

Protective effect of nutmeg aqueous extract against experimentally-induced hepatotoxicity and oxidative stress in rats

Mohammed Abdul Kareem^{1,4}, Saayi Krushna Gadhamsetty^{2,4}, Althaf Hussain Shaik³, E. Maruthi Prasad⁴, Lakshmi Devi Kodidhela⁴

Departments of Biochemistry, ¹Indira Gandhi National Open University, New Delhi, ³Chonbuk National University Medical School, Jeonju, South Korea, ⁴Sri Krishnadevaraya University, Anantapur, Andhra Pradesh, India, ²Department of Microbiology-Immunology, Northwestern University, Chicago, USA

ABSTRACT

Background: Nutmeg a well-known spice used as a folk medicine in India to treat stomach ailments. Worldwide it is commonly used for food preservation and fragrance. Abundant references were given for nutmeg in ayurveda, unani, and siddha as a single drug or as an important constituent in formulations. **Objective:** In the present study, nutmeg aqueous extract (NMAET) was evaluated against isoproterenol (ISO)-induced hepatotoxicity and oxidative stress. **Materials and Methods:** Antioxidant enzymes, liver functions tests, and lipid profile tests were performed using standard procedures. Histological examination of liver was done by fixing in formaldehyde solution and hematoxylin staining. **Results:** Oral administration of NMAET effectively inhibited the ISO-induced changes in the activities of hepatic marker and antioxidant enzymes in plasma and heart tissue along with lipid peroxidation levels. The liver sections of ISO administered rats showed massive fatty changes, necrosis, ballooning degeneration, and broad infiltration of the lymphocytes and the loss of cellular boundaries; these changes were completely absent in groups treated with extract. Analysis of variance and Duncan's Multiple Range tests were used to perform statistical analysis. **Conclusion:** Results suggest that the NMAET possess significant potential as hepatoprotective and antioxidative agent against ISO-induced damage in rats.

Key words: Antioxidant enzymes, isoproterenol, lipid peroxidation, marker enzymes and hepatoprotective agent

INTRODUCTION

Liver is a vital and major metabolic organ repeatedly exposed to various drugs, chemicals, and toxins by virtue of our lifestyle activities. It is essential to protect liver by using a successful hepatoprotective agent. Owing to the absence of effective liver protective drugs in allopathic medicine, herbal drugs and extracts play an important role in the management

of liver disorders. The model of isoproterenol (ISO)-induced myocardial infarction (MI) is considered as one of the most widely used experimental model to study the beneficial effects of many drugs and cardiac function.^[1] ISO is a synthetic catecholamine and β -adrenergic agonist, which causes severe oxidative stress, resulting in infarct like necrosis. It is structurally similar to epinephrine [adrenaline- [Figure 1] and acts selectively on β -receptors.^[2] Enhanced free radical (FR) formation and lipid peroxide accumulation have been proposed as one of the possible biochemical mechanisms for damage during ISO administration^[3]

MI produces significant abnormal liver functioning.^[4] Liver is often affected by various drugs and pollutants,

Address for correspondence:

Dr. Mohammed Abdul Kareem, School of Sciences, Indira Gandhi National Open University, New Delhi - 110 068, India. E-mail: abdul.kareem@ignou.ac.in

Received: 10-Feb-2013

Revised: 26-Mar-2013

Accepted: 13-May-2013

Access this article online	
Quick Response Code: 	Website: www.jaim.in
	DOI: 10.4103/0975-9476.123704

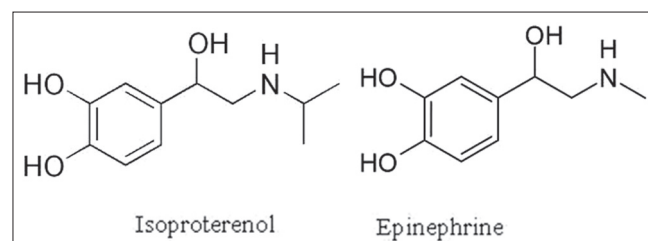


Figure 1: Isoproterenol, epinephrine

which can damage and weaken it eventually leading to hepatitis or cirrhosis.^[5] Due to several undesirable effects of synthetic drugs, the world population is moving toward medicines derived from locally available native extracts of edible plant parts and plants products. Nutmeg is the dried seed kernel of *Myristica fragrans* (family: Myristicaceae), an evergreen aromatic tree cultivated in many tropical countries and is widely used as a spice and also to flavor many kinds of baked foods and vegetables. Recent studies indicate that nutmeg is useful against damage caused by gamma radiation and also in the improvement of mouse memory.^[6,7] Anti-inflammatory activity of nutmeg has also been reported in addition to its insulin-like biological activity.^[8,9] Nutmeg has been reported to possess cardio tonic property in the ancient and traditional system of Indian medicine, which prompted us to select the nutmeg aqueous extract (NMAET) to treat hepatotoxicity associated with ISO-induced oxidative stress. In a recent study antihyperglycemic and hyperlipidemia activities of NMAET were proven.^[10] The aim of present study is to evaluate the hepatoprotective effect of NMAET against ISO-induced oxidative stress. Adding up to this lipid peroxidation (LPO) and liver histopathology were examined to assess the protective effect of NMAET in ISO-induced hepatotoxicity.

MATERIALS AND METHODS

Chemicals

ISO was purchased from Sigma-Aldrich (USA). All other chemicals were of analytical grade and were supplied by Sisco Research Laboratories (Mumbai, India).

Animal ethical committee approval

The groups include control, NMAET treatment, NMAET pretreatment, and ISO administered were done with the approval of institutional animal ethic committee (Regd. No. 470/01/a/CPCSEA, dated 24th Aug 2001) and as per guidelines.

Plant material

Fresh nutmegs (500 g) were procured from local market. Nutmeg was verified with specimens available at the botanical herbarium of the University. They were air dried and powdered in an electric blender. The powder was boiled in distilled water. After filtration through Whatmann No. 40 filter paper, the extract was evaporated to dryness by slow heating and continuous stirring in a water bath. The dark brown residue left behind was collected and was used for studies.

Experimental induction of oxidative stress

Adult male rats of Wistar strain weighing 120-150 g were procured from National Centre for Animal Science,

National Institute of Nutrition, Hyderabad, India. Animals were housed under standard laboratory conditions with relative humidity 65% \pm 2%, temperature 23°C \pm 2°C and 12:12 h light: dark cycle. They were fed with standard rodent pellet diet (M/s. Hindustan Lever Ltd., Mumbai, India) and water *ad libitum*. After acclimatization for a month, the rats were divided into four groups of eight animals in each and caged individually. Oxidative stress was induced by subcutaneous (s.c.), injection of ISO 85 mg/kg body weight (BW), dissolved in physiological saline (0.2 mL), twice at an interval of 24 h for 2 days.^[11]

Experimental design

Control-Rats fed with standard rodent pellet diet and received physiological saline s.c. for 2 days after 30 days experimental period. ISO administered-Rats fed with standard rodent pellet diet and administered ISO at a dose of 85 mg/kg BW, s.c., dissolved in physiological saline twice at an interval of 24 h for 2 days. NMAET Treatment-Rats fed with standard rodent pellet diet and treated with NMAET orally (100 mg/kg BW/day for a period of 30 days). NMAET pretreatment-Rats fed with standard rodent pellet diet and treated with NMAET orally (100 mg/kg BW/day for a period of 30 days) and then ISO at the dose mentioned for ISO-administered group.

The extract dose used in this study was fixed based on the acute oral toxicity study as well as reports published on the biological effects of *M. fragrans* (nutmeg) extract.^[8] Extract treated and extract pretreated animals received the extract orally by gastric tube, every day in between 8 and 9 am for a period of 30 days.

Collection of sample and preparation of tissue

At the end of experimental period the animals were fasted for 12 h to minimize dietary influences and sacrificed around 8 am by cervical dislocation. Blood was drawn by cardiac puncture in sterile syringes and then transferred in to Eppendorf tubes containing heparin. Plasma was separated from cells by centrifugation at 3000 rpm for 10 min. A small portion of liver tissue was removed, washed thoroughly with ice-cold saline, and suspended in formalin buffer for histological examinations in polypropylene containers. A total of 100 mg of wet heart tissue was weighed accurately and homogenized in 5 mL of 0.1 M Tris-HCl buffer (pH 7.4) in ice-cold condition. The homogenate was centrifuged at 2500 g and the clear supernatant was taken for the assay of antioxidant and cardiac marker enzymes along with LPO. From the heart tissue lipids were extracted by the method of Folch *et al.*^[12]

Acute oral toxicity and LD50

Acute oral toxicity study was performed for NMAET as per OECD-423 guidelines using adult male albino rats of

Wistar strain.^[13] The animals were fasted for overnight prior to the experiment and maintained under standard conditions. NMAET extract was administered orally in increasing dose and found safe up to 1000 mg/kg body weight. The animals were observed for toxic symptoms such as locomotion, convulsions, behavioral changes, and mortality for 72 h. NMAET showed no lethal effect at least up to a dose of 1000 mg/kg body weight indicating that LD50 if any should be higher than this dose.

In vitro free radical scavenging studies

The *in vitro* FR scavenging activity of the extract was measured in terms of hydrogen donating or radical scavenging ability using the stable radical 1,1-diphenyl-2-picrylhydrazyl (DPPH),^[14] different concentrations of extract (50-600 µg) in 0.3 mL of distilled water was mixed with 2.7 mL of DPPH solution and shaken vigorously and allowed to stand at room temperature for 30 min. Systems devoid of extract were considered as control. The absorbance was measured at 517 nm. The FR scavenging capacity was determined by comparing the absorbance of treatment with that of the control where as the inhibition of LPO by the method of Sujioka *et al.*^[15] The reaction mixture containing 1.0 mL of rat heart homogenate, 0.3 mL of ferric chloride, 0.3 mL of ADP-Na₂, 0.4 mL of ascorbic acid, 0.2 mL of extract with different concentrations (150-3000 µg) and 0.8 mL of KCl was incubated for 20 min at 37°C. A system with distilled water, devoid of extract served as control. A total of 1 mL from each of test and control were treated with 4.0 mL of Thiobarbutyric acid, 2.0 mL of Trichloroacetic acid and heated in a boiling water bath for 30 min. After cooling, the absorbance of supernatant was read at 535 nm and the per cent inhibition of LPO was determined by comparing with control.

Measurement of liver function enzymes

Marker enzyme activities were assayed in both plasma and heart tissue homogenate by using the following methods. The activity of lactate dehydrogenase (LDH) was measured by the method of Teitz.^[16] Creatinine kinase (CK) was assayed by the procedure of Henry,^[17] Aspartate transaminase (AST) was determined by the method of Reitman and Frankel,^[18] Alanine transaminase (ALT) was determined by the method of Reitman and Frankel,^[18] Alkaline phosphatase (ALP) was determined by the procedure of Teitz,^[16] γ-glutamyl transferase was assayed by the method of Rosalki and Tarlow.^[19]

Measurement of antioxidant status

The amount of glutathione (GSH) in the heart tissue homogenate was assayed by Ellmans method,^[20] values are expressed as µg GSH/mg protein. GSH-dependent heart tissue antioxidant enzyme glutathione peroxidase (GPX)

was measured by Rotruck *et al.*, method,^[21] the activity was expressed as µgm of GSH consumed/min/mg protein. The activity of glutathione-S-transferase (GST) was measured by Habig *et al.*, method,^[22] expressed as mmoles of CDNB-GSH conjugate formed/min/mg protein. The activity of superoxide dismutase (SOD) was estimated by the method of Soon and Tan,^[23] the specific activity was expressed as units/min/mg protein. Catalase (CAT) activity was assayed by Chance method,^[24] the activity was expressed as mmoles of H₂O₂ decomposed/min/mg protein. LPO was estimated in terms of thiobarbutyric acid reactive species using malondialdehyde as standard by the method of Ohkawa *et al.*^[25]

Hepatotoxicity studies

Liver tissue histological analysis was carried out by method of Raghuramulu *et al.*,^[26] briefly tissue fixation was done immediately after removal from the body with 10% neutral buffered formaldehyde solution (pH 7.0). Tissue processing carried out at specific time intervals with desired solutions for dehydration, clearing and paraffin infiltration. The container was then filled with melted paraffin and allowed to cool so that it can form block of paraffin with the tissue. The block was trimmed so that to remove the excess paraffin overlaying the piece of tissue, the sections were cut at 5 µm thickness and was mounted on clean glass slides, which had been smeared with a drop of Mayer's egg albumin. It was then dried on a hot plate at about 50°C for 30 min. The sections on the slides were then subjected to staining with hematoxylin and eosin.

Statistical analysis

Statistical analysis was performed by using one-way analysis of variance followed by Duncan's multiple range test. Results were expressed as mean ± standard error of mean for eight rats in each group. A value of $P < 0.05$ was considered statistically significant.

RESULTS

According to oral toxicity studies the NMAET did not cause any mortality up to 1000 mg/kg and considered as safe. No lethality or any toxic reactions were found up to the end of the study period. Data presented in Table 1 illustrates a significant decrease in the concentration of DPPH radical and inhibit the formation of lipid peroxides induced by Fe³⁺/ADP/ascorbate system [Table 1].

NMAET treatment *per se* did not alter the activities of cardiac and liver marker enzymes like LDH, CK, AST, ALT, ALP, and GGT when compared to control [Table 2]. In ISO administered rats, a significant ($P < 0.05$) elevation in the activities of these marker enzymes was observed by 64.74%, 68.45%, 88.55%, 91.60%, 232%, and 46%,

respectively, when compared to control. The activities of marker enzymes were significantly ($P < 0.05$) reduced by 35.19%, 24.87%, 32.80%, 39.42%, 56.64%, and 21.62% for LDH, CK, AST, ALT, ALP, and GGT, respectively in pretreated group compared to ISO administered group [Table 2].

Table 3 shows the activities of marker enzymes such as LDH, CK, AST, ALT, ALP, and GGT in the heart tissue of

control, ISO administered treated and pretreated rat groups. ISO administration alone showed a significant ($P < 0.05$) decrease in the activities of LDH, CK, AST, ALT, ALP, and GGT by 44.03%, 38.90%, 43.54%, 30.24%, 55.3%, and 47.9%, respectively when compared to control. Pretreatment of rats with NMAET significantly ($P < 0.05$) increased the level of these marker enzymes by 56%, 44.44%, 55.2%, 21.87%, 52.38%, and 66.52%, respectively for LDH, CK, AST, ALT, ALP, and GGT compared to ISO administered rats [Table 3].

Data presented in Table 4 indicate the levels of GSH and activities of GSH-dependent antioxidant enzymes (GPX and GST) and antiperoxidative enzymes (SOD, CAT) in the heart tissue and changes in LPO levels in the heart and plasma [Table 4] of control and experimental rats. There is a significant ($P < 0.05$) decrease in the level of GSH (49.90%) and activities of GSH-dependent enzymes, GPX and GST by 35.18% and 43%, respectively in the heart tissue. Further it is observed that significant ($P < 0.05$) decrease in the activities of antiperoxidative enzymes, SOD, CAT by 32.17, 52.48%, respectively in the heart tissue noted along with a concomitant increase in the LPO in the heart tissue as well

Table 1: In vitro antioxidant activities of nutmeg aqueous extract

Conc. of NMAET µg/0.2 mL	% inhibition of lipid peroxide formation	Scavenging capacity of 1,1-diphenyl-2-picrylhydrazyl (%)
50	1.80	24.18
100	ND	36.90
200	5.55	54.62
300	12.36	58.62
400	31.65	65.81
500	33.21	65.97
600	36.07	67.20
800	54.60	72.45
1000	61.66	72.81

NMAET=Nutmeg aqueous extract

Table 2: Effect of nutmeg aqueous extract treatment and pretreatment on plasma marker enzymes in control and experimental groups

Groups	LDH	CK	AST	ALT	ALP	GGT
Control	84.5±2.4 ^a	231.7±3.4 ^a	23.6±1.2 ^a	13.1±0.6 ^a	80.6±1.4 ^a	7.6±0.8 ^a
ISO	139.2±1.9 ^b	390.3±6.1 ^b	44.5±1.1 ^b	25.1±1.2 ^b	268.3±4.5 ^b	11.1±0.5 ^b
NMAET	86.7±2.8 ^a	232.2±2.1 ^a	22.8±1.4 ^a	13.2±1.4 ^a	80.6±1.1 ^a	7.5±0.4 ^a
NMAET+ISO	90.2±2.3 ^c	293.3±2.0 ^c	29.9±1.7 ^c	15.2±1.1 ^c	116.3±3.1 ^c	8.7±0.6 ^c

Values are mean±standard error of the mean for eight rats in each group, Values in the same column not sharing a common superscript (a-c) differ significantly $P < 0.05$ with each other. All the values are expressed as IU/L, ALP=Alkaline phosphatase, ALT=Alanine transaminase, AST=Aspartate transaminase, CK=Creatinine kinase, ISO=Isoproterenol, GGT=Gamma-glutamyl transferase, NMAET=Nutmeg aqueous extract, LDH=Lactate dehydrogenase

Table 3: Effect of nutmeg aqueous extract treatment and pretreatment on heart tissue marker enzymes in control and experimental groups

Groups	LDH	CK	AST	ALT	ALP	GGT
Control	118.15±3.1 ^a	9.87±0.3 ^a	18.6±0.2 ^a	40.11±1.2 ^a	4.7±0.4 ^a	4.59±0.5 ^a
ISO	66.12±1.2 ^b	6.03±0.6 ^b	10.5±0.3 ^b	28.02±1.2 ^b	2.1±0.2 ^b	2.39±0.9 ^b
NMAET	116.27±6.1 ^a	9.75±0.2 ^a	18.8±0.4 ^a	41.02±0.9 ^a	4.6±0.8 ^a	4.51±0.7 ^a
NMAET+ISO	103.1±5.1 ^c	8.71±0.4 ^c	16.3±0.1 ^c	34.15±1.1 ^c	3.2±0.3 ^c	3.98±0.2 ^c

Values are mean±standard error of the mean for eight rats in each group, Values in the same column not sharing a common superscript (a-c) differ significantly $P < 0.05$ with each other. Expressed as U min⁻¹ mg protein⁻¹, ALP=Alkaline phosphatase, ALT=Alanine transaminase, AST=Aspartate transaminase, CK=Creatinine kinase, ISO=Isoproterenol, GGT=Gamma-glutamyl transferase, NMAET=Nutmeg aqueous extract, LDH=Lactate dehydrogenase

Table 4: Effect of nutmeg aqueous extract treatment and pretreatment on heart tissue antioxidant enzymes in control and experimental groups

Parameters	Control	ISO	NMAET	NMAET+ISO
SOD (U/min/mg protein)	37.11±2.12 ^a	25.17±2.11 ^b	40.19±3.14 ^a	32.12±1.09 ^c
CAT (µ mol of H ₂ O ₂ decomposed/min/mg protein)	26.56±0.36 ^a	12.62±0.14 ^b	28.35±0.39 ^a	24.42±0.76 ^c
GSH (µg of GSH/mg protein)	26.17±0.38 ^a	13.11±0.36 ^b	29.76±0.45 ^a	20.16±0.42 ^c
GPX (m mol of GSH consumed/min/mg protein)	48.52±2.14 ^a	31.45±2.58 ^b	52.65±2.39 ^a	40.75±3.42 ^c
GST (µ mol of GSH-CDNB conjugate formed/min/mg protein)	16.23±0.17 ^a	9.25±0.11 ^b	17.26±0.16 ^a	14.21±0.15 ^c

Values are mean±standard error of the mean M for eight rats in each group, Values in the same row not sharing a common superscript (a-c) differ significantly $P < 0.05$ with each other, CAT=Catalase, GPX=Glutathione peroxidase, GSH=Glutathione, GST=glutathione-S-transferase, ISO=Isoproterenol, NMAET=Nutmeg aqueous extract, SOD=Superoxide dismutase

as in plasma by 73.55% and 70.41%, respectively occurred in ISO administered rats as compared to controls [Table 4].

Treatment with NMAET alone increased the activities of antioxidant enzymes by 8.51%, 6.34%, 8.29%, and 6.73%, respectively for GPX, GST, SOD, and CAT along with GSH (13.71%). NMAET treatment also prevented the increase in LPO levels by 5.76% and 5.47% in heart tissue and plasma [Figure 2]. However, NMAET treatment alone induced a significant increase in myocardial antioxidant enzyme activities when compared with the control group. The pronounced oxidative stress effect of ISO is significantly ($P < 0.05$) attenuated by pretreatment of animals with NMAET by 29.57%, 53.62%, 27.61%, 93.50%, and 53.77%, respectively for GPX, GST, SOD, CAT, and GSH along with LPO decrease in heart tissue and plasma by 37.89% and 16.72%, respectively. However, NMAET treatment alone induced a significant increase in myocardial antioxidant enzyme activities as compared with the control group. The pronounced oxidative stress effect of ISO is significantly attenuated in animals treated with NMAET [Figure 2].

The liver sections [Figure 3] of ISO administered rats showed massive fatty changes, necrosis, ballooning degeneration, and broad infiltration of the lymphocytes and the loss of cellular boundaries. The histological architecture of liver sections of NMAET treated rats showed lobular pattern with a mild degree of fatty change and lymphocyte infiltration almost similar to that of control. There is minimal damage, with mild swelling of hepatic cells was seen in NMAET pretreated rats. Thus, NMAET pretreatment retained near normal architecture of the liver when compared with ISO administered group [Figure 3].

DISCUSSION

When myocardial cells containing LDH, CK, AST, ALT, ALP, and GGT are damaged or destroyed due to deficient oxygen supply or glucose, the cell membrane becomes abnormally permeable or may rupture, which results in the leakage of enzymes.^[27] ISO administration in rats causes gross, microscopic myocardial necrosis, and depletion of tissue enzymes in heart and liver. As a result of necrosis and leakage, the levels of diagnostic indicators of MI and hepatotoxicity, such as LDH, CK, AST, ALT, ALP, and GGT will increase [Table 2] in plasma.^[28] While evaluating the drugs for their beneficial effects against MI, it is necessary to assess their effect on other vital organs like liver. Size of infarction can be measured by the sensitive indices of MI such as plasma transaminases, CK and LDH.^[29] In ISO-administered rats, the increased activities of plasma transaminases, CK

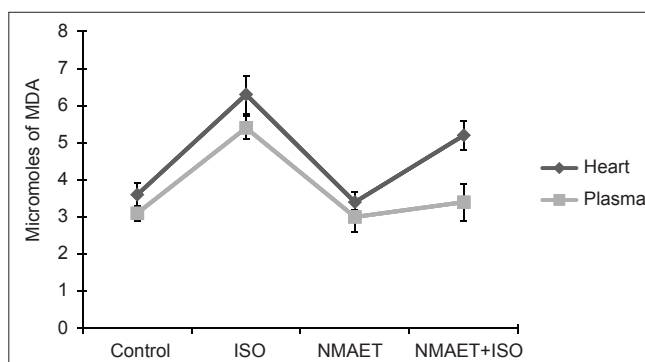


Figure 2: Changes in the lipid peroxidation levels

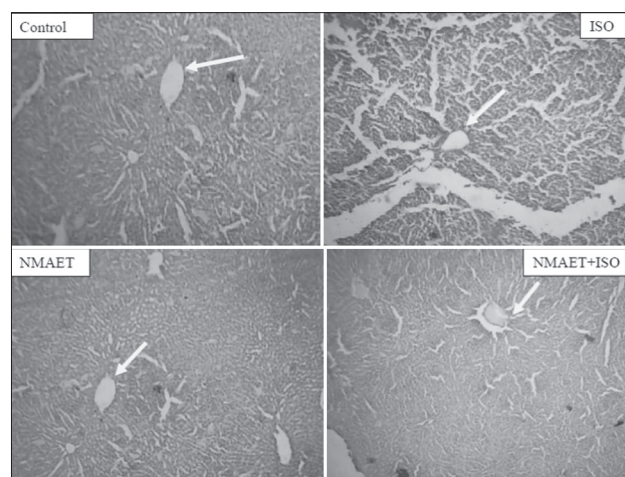


Figure 3: Histopathological examination

and LDH accompanied by their concomitant reduction in the heart homogenate [Table 3] confirm the onset of oxidative damage. The significant decrease of marker enzymes in the plasma in pretreated group compared to ISO-administered group suggests that NMAET prevents the damage induced by ISO and hence avoids leakage of marker enzymes. High levels of GGT and transaminases have been associated in populations with increased risk of atherosclerotic CVD.^[30] GGT is one of the enzymes used to monitor the liver damage. Significant ($P < 0.05$) elevation of plasma GGT in ISO-administered rats confirms damage and injury to the hepatocytes.

Present study is in accordance with earlier reported study,^[31] which has shown that the amount of diagnostic markers present in plasma is directly proportional to the number of necrotic cells present in the cardiac tissue. Cytosolic macromolecules like enzymes, proteins and polysaccharides leak from the necrotic myocardium and hepatocytes. These molecules because of their tissue specificity and catalytic activity are the best indicators of cardiac and hepatic damage. Increased release of these markers into systemic circulation observed in the present study reflects nonspecific alterations in the hepatic and myocardial membrane integrity and permeability as a response to β

adrenergic stimulation.^[32] NMAET pretreatment decreased the activities of these marker enzymes in ISO-administered rats, this could be due to the FR scavenging property of the extract in the presence of antioxidative phytochemicals such as flavonoids, alkaloids, and especially by myristicin. Hepatoprotective effect of myristicin from nutmeg on lipopolysaccharide/D-galactosamine-induced liver injury was experimentally evident,^[33] and the same has been proven by our *in vitro* FR scavenging activity and inhibition of LPO [Figure 2] by the NMAET. This finding strongly supports NMAET as a hepatoprotective protective agent. Thus, rats pretreated with NMAET showed cardioprotective activity which is evidenced by significant restoration of activities of myocardial CK along with other marker enzymes.

FR scavenging enzymes such as CAT, SOD, GPx, and GST are the first-line cellular defense against oxidative injury, decomposing O₂ and H₂O₂ before interacting to form the more reactive hydroxyl radical. The equilibrium between these enzymes and ROS is an important process for the effective removal of oxidative stress in intracellular organelles. The second line of defense consists of the nonenzymatic scavengers viz. ascorbic acid, α -tocopherol, ceruloplasmin, and sulfhydryl containing compounds, which scavenge residual FR that escapes decomposition by the antioxidant enzymes. Our results demonstrate that ISO administration reduced the content of protein sulfhydryl group and GSH in cardiac tissue and this observation is in agreement with earlier findings,^[34] and the decreased activity of GPx and GST in ISO-administered group might be correlated to decreased availability of its substrate, GSH.

The data obtained in this study show remarkable decrease in the concentration of DPPH due to scavenging ability of NMAET. The FR scavenging activity was gradually increased with increase in concentration of NMAET from 50 to 600 μ g/mL. The results indicated the noticeable effect of NMAET on scavenging DPPH FR in a dose-dependent manner. Based on the data obtained from this study, NMAET is a powerful FR inhibitor or scavenger, as well as a primary antioxidant that reacts with FR, which may limit FR damage. Scavenging of DPPH radical is related to the inhibition of LPO.^[35] The extract was found to inhibit lipid peroxides generated by the induction of Fe³⁺/ADP/ascorbate in a dose-dependent manner as presented in the Table 1. FR formed as a byproduct of many biochemical reactions (electron transport chain, catabolic steps in mitochondria, microsomal reactions, etc) initiate this phenomenon in a chain reaction. FR-induced LPO has gained much importance because of its involvement in several pathologies such as aging, atherosclerosis.^[36]

Due to the decreased antioxidant enzyme activities, the FR is not neutralized and hence myocardium shows enhanced susceptibility to LPO in the presence of promoters of LPO. However, NMAET pretreatment and treatment prevented the decrease in antioxidants and antioxidant enzyme levels [Table 4]. A significant ($P < 0.05$) decrease in myocardial SOD and GPx activity is observed in ISO administered rats when compared to control group. Our results are in agreement with previously reported studies.^[37] Elevated LPO is an important pathogenic event in oxidative stress and in various diseases. ISO-induced generation of FR and ROS cause damage to the heart which is evident from the significant ($P < 0.05$) increase in LPO in the heart tissue and plasma [Figure 2] of ISO-administered rats indicating a state of oxidative stress. Pretreatment with NMAET in ISO administered rats reduced the levels of LPO in both heart tissue and plasma when compared with ISO alone administered rats suggesting its antioxidative and FR scavenging activity. In NMAET alone treated rats, the levels of LPO were lowered than the control rats which supports the scavenging action of extract. The postulated mechanisms including myocardial necrosis and apoptosis as well as FR generation may contribute to the pathogenesis of catecholamine-induced MI.^[38]

An imbalance between prooxidant and antioxidant levels in the body gives rise to cellular oxidative stress that plays an important role in the pathophysiology of the disease.^[39] We found that the pronounced oxidative stress effect of ISO was significantly reduced with NMAET. Moreover, NMAET treatment increases antioxidant enzyme status as compared with the control group. These findings proved not only an antioxidant property of extract but it also clearly improved “the endogenous antioxidant reserve.” The enhancement effect of NMAET on antioxidant activity has been reported for the first time in our study, and our results are in agreement with *in vitro* studies.^[40] Increased antioxidant status and decreased LPO are probably due to the presence of the isoprenoid unit in the structure of terpinene-4-ol and myristicin present in the NMAET. The unpaired electron present in the O₂ and H₂O₂ generated during ISO-induced toxicity might have been trapped for dismutation by its FR scavenging isoprenoid unit.

Terpinene-4-ol is lipophilic in nature could be compared with any other lipophilic agent such as vitamin E, antipyrin, and nifedine in exerting membrane stabilizing action. Hence, it is possible that terpinene-4-ol likewise protects cell membranes from necrotic damage by its membrane stabilizing action. Similar results were reported by Senthil *et al.*,^[27] who carried out the protective effect of oleanolic acid.

Histopathological sections of liver [Figure 3] showed increased tissue damage in ISO alone administered rats,

whereas the damage is very much minimized in NMAET pretreatment. Histopathological study of liver from the control group animals showed a normal hepatic architecture with distinct hepatic cells, sinusoidal spaces, and a central vein. However, ISO-administered rats exhibited severe histopathological changes, such as centrilobular hepatic necrosis, fatty change, apoptotic bodies, and ballooning degeneration [Figure 3]. Pretreatment with 100 mg of NMAET showed significant recovery, from ballooning degeneration, fatty change, centrilobular hepatic necrosis, and also apoptotic bodies were scarce. This could be due to the hepatoprotective property of flavonoids present in NMAET and this is in accordance with earlier reports of Morita *et al.*^[33] The liver tissue sections of NMAET-treated animals [Figure 3] showed no change in structure and are similar to that of the control group, indicating that NMAET is free from toxicity and an effective hepatoprotective agent. Limitation of the study includes lack of assessment between conventionally used hepatotoxicants like CCl₄ and paracetamol with that of ISO-induced hepatotoxicity.

CONCLUSION

Nutmeg has been shown to possess wide range of medicinal values in ayurveda and unani system of medicine. The organic extract of the nutmeg is used as anti-inflammatory, diuretic and mimics insulin activity. The present communication is an endeavor in the direction of evaluating its antioxidant and hepatic protection against ISO-induced oxidative damage in rats. Thus, it is concluded that NMAET protects experimental hepatic injury as revealed by the amelioration of marker enzymes along with hepatoprotective effect, without any clinical complications as shown by oral toxicity studies. Overall results obtained in this study reveal that NMAET being cardioprotective agent also protects liver injury in MI induced by ISO associated oxidative stress. Hence, it can be used as a value-added pharmacological agent for managing risks associated with hepatic pathophysiology.

ACKNOWLEDGMENTS

We acknowledge UGC, New Delhi for funding this work as a major research project (UGC Letter no. F.No. 36-213/2008) and Sri Krishnadevaraya University for providing required laboratory facilities and extend our heartfelt wishes to Prof PBN Charyulu and Prof. T Pullaiah of SK University for their useful discussions. We extend our gratitude to NIN, Hyderabad for providing animals.

REFERENCES

- Grimm D, Elsner D, Schunkert H, Pfeifer M, Griese D, Bruckschlegel G, *et al.* Development of heart failure following isoproterenol administration in the rat: Role of renin-angiotensin system. *Cardiovasc Res* 1998;37:91-100.
- Wexler BC. Myocardial infarction in young vs old male rats: Pathophysiologic changes. *Am Heart J* 1978;96:70-80.
- Paritha A, Devi CS. Effect of α -tocopherol on isoproterenol-induced changes in lipid and lipoprotein profile in rats. *Indian J Pharmacol* 1997;29:399-404.
- Thirupurasundari CJ, Jayalakshmi R, Niranjali Devaraj S. Liver architecture maintenance by tincture of Crataegus against isoproterenol-induced myocardially infarcted rats. *J Med Food* 2005;8:400-4.
- Zimmerman HJ, Ishak KG, Mac Sween R, Anthony PP, Scheurer PJ, Burt AD, *et al.* Hepatic Injury Due to Drugs and Toxins, in *Pathology of Liver*. Edinburgh: Churchill Livingstone; 1994. p. 563-634.
- Sharma M, Kumar M. Radioprotection of swiss albino mice by *myristica fragrans* houtt. *J Radiat Res* 2007;48:135-41.
- Parle M, Dhingra D, Kulkarni SK. Improvement of mouse memory by *Myristica fragrans* seeds. *J Med Food* 2004;7:157-61.
- Olajide OA, Ajayi FF, Ekhelar AI, Awe SO, Makinde JM, Alada AR. Biological effects of myristica fragrans (Nutmeg) extract. *Phytother Res* 1999;13:344-5.
- Broadhurst CL, Polansky MM, Anderson RA. Insulin-like biological activity of culinary and medicinal plant aqueous extracts *in vitro*. *J Agric Food Chem* 2000;48:849-52.
- Abdul KM, Saayi KG, Altaf HS, Lakshmi DK. Effect of Nutmeg aqueous extract on hyperglycaemia, hyperlipidaemia and cardiac histology associated with isoproterenol-induced myocardial infarction in rats. *Trop J Pharma Res* 2009;8:337-44.
- Rona G, Chappel CI, Balazs T, Gaundry R. An infarct like myocardial lesion and other true manifestation produced by isoproterenol in the rat. *AMA Arch Pathol* 1959;67:443-55.
- Folch J, Ascoli I, Lees M, Meath JA, LeBaron N. Preparation of lipid extracts from brain tissue. *J Biol Chem* 1951;191:833-41.
- Ecobichon DJ. *The Basis of Toxicology Testing*. New York: CRC Press; 1997. p. 43-86.
- Okada Y, Okada M. Scavenging effect of water soluble proteins in broad beans on free radicals and active oxygen species. *J Agric Food Chem* 1998;46:401-6.
- Sujjoka K, Shimosegawa Y, Nakaro M. Estrogens as natural antioxidants of membrane phospholipid peroxidation. *FEBS Lett* 1987;210:37-9.
- Teitz NW. In: *Fundamentals of Clinical Chemistry*. Philadelphia: WB Saunders and Company; 1976. p. 602-3.
- Henry JB. In: *Clinical diagnosis and management laboratory methods*. Philadelphia: WB Saunders and Company; 1979. p. 365.
- Reitman S, Frankel S. A colorimetric method for the determination of serum glutamic oxaloacetic and glutamic pyruvic transaminase. *Am J Clin Pathol* 1957;28:56-63.
- Rosalki SB, Tarlow D. Optimized determination of gamma-glutamyl transferase by reaction-rate analysis. *Clin Chem* 1974;20:1121-4.
- Ellman GL. Tissue sulphhydryl groups. *Arch Biochem Biophys* 1959;82:70-7.
- Rotruck JT, Pope AL, Ganther HE, Swanson AB, Hafeman DG, Hoekstra WG. Selenium: Biochemical role as a component of glutathione peroxidase. *Science* 1973;179:588-90.
- Habig WH, Pabst MJ, Jakoby WB. Glutathione-S-transferases. The first enzymatic step in mercapturic acid formation. *J Biol Chem* 1974;249:7130-9.
- Soon YY, Tan BK. Evaluation of the hypoglycemic and antioxidant activities of *Morinda officinalis* in streptozotocin-induced diabetic rats. *Singapore Med J* 2002;43:77-85.
- Chance B. Catalase and peroxidases. Part II. Special methods. *Methods Biochem Anal* 1954;1:408-12.
- Ohkawa H, Ohishi N, Yagi K. Assay for lipid peroxides in animal tissues by thiobarbituric acid reaction. *Anal Biochem* 1979;95:351-8.
- Raghuramulu N, Madhavan NK, Kalyan SS. *A manual of Laboratory technique*. Hyderabad: National Institution of Nutrition; 1983. p. 205-6.

27. Senthil S, Sridevi M, Pugalendi KV. Cardio protective effect of oleanolic acid on isoproterenol induced myocardial ischemia in Rats. *Toxicol Pathol* 2007;35:418-23.
28. Rajadhurai M, Prince PS. Comparative effect of Aegle marmelos extract and alpha tocopherol on serum lipids, lipid peroxides and cardiac marker enzyme levels in rats with isoproterenol-induced myocardial infarction. *Singapore Med J* 2005;46:2-78.
29. Sheela SC, Shyamala DC. Protective effect of Abana, a polyherbal formulation, on isoproterenol induced myocardial infarction in rats. *Indian J Pharmacol* 2000;32:198-201.
30. Ruttman E, Brant LJ, Concin H, Diem G, Rapp K, Ulmer H. Vorarlberg Health Monitoring and Promotion Program Study Group. Gamma glutamyl transferase as a risk factor for cardiovascular disease mortality: an epidemiological investigation in a cohort of 163, 944 Austrian adults. *Circulation* 2005;112:2130-7.
31. Anandan R, Asha KK, Ammu K, Suseela M, Nair PG. Effects of peroxidised PUFA on tissue defense system in experimentally induced myocardial infarction in rats. In: *Seafood safety. Society of Fisheries Technologists (India)* 2003;5:330-5.
32. Dhandapani N, Ganesan B, Anandan R, Jaya KR, Raja PD, Anbin ER. Synergistic effects of squalene and polyunsaturated fatty acid concentrate on lipid peroxidation and antioxidant status in isoprenaline-induced myocardial infarction in rats. *Afr J Biotechnol* 2007;6:1021-7.
33. Morita T, Jinno K, Kawagishi H, Arimoto Y, Sukanuma H, Inakuma T, *et al.* Hepatoprotective effect of myristicin from nutmeg (*Myristica fragrans*) on lipopolysaccharide/d-galactosamine-induced liver injury. *J Agric Food Chem* 2003;511:1560-5.
34. Nirmala C, Puvanakrishnan R. Effect of curcumin on certain lysosomal hydrolases in isoproterenol induced myocardial infarction in rats. *Biochem Pharmacol* 1996;51:47-51.
35. Rekka E, Kourounakis PN. Effect of hydroxyl rutenosides and related compounds on lipid peroxidation and free radical scavenging activity. Some structural aspects. *J Pharm Pharmacol* 1991;43:486-91.
36. Rowley DA, Halliwell B. Superoxide-dependent formation of hydroxyl radicals in the presence of thiol compounds. *FEBS Lett* 1982;138:33-6.
37. Rathore N, John S, Kale M, Bhatnagar D. Lipid peroxidation and antioxidant enzymes in isoproterenol induced oxidative stress in rat tissues. *Pharmacol Res* 1998;38:297-303.
38. Mann DL. Basic mechanisms of disease progression in the failing heart: The role of Excessive adrenergic derive. *Prog Cardiovasc Dis* 1998;41:1-8.
39. Dhalla NS, Temsah RM, Netticadan T. Role of oxidative stress in cardiovascular diseases. *J Hypertens* 2000;18:655-73.
40. Chatterjee S, Niaz Z, Gautam S, Adhikari S, Prasad S, Arun S. Antioxidant activity of some phenolic constituents from green pepper (*Pipernigrum L.*) and fresh nutmeg mace (*Myristica fragrans*). *Food Chem* 2007;101:515-23.

How to cite this article: Kareem MA, Gadhamsetty SK, Shaik AH, Prasad EM, Kodidhela LD. Protective effect of nutmeg aqueous extract against experimentally-induced hepatotoxicity and oxidative stress in rats. *J Ayurveda Integr Med* 2013;4:216-23.

Source of Support: Funded by UGC as Major research Project, **Conflict of Interest:** None declared.

Author Help: Reference checking facility

The manuscript system (www.journalonweb.com) allows the authors to check and verify the accuracy and style of references. The tool checks the references with PubMed as per a predefined style. Authors are encouraged to use this facility, before submitting articles to the journal.

- The style as well as bibliographic elements should be 100% accurate, to help get the references verified from the system. Even a single spelling error or addition of issue number/month of publication will lead to an error when verifying the reference.
- Example of a correct style
Sheahan P, O'leary G, Lee G, Fitzgibbon J. Cystic cervical metastases: Incidence and diagnosis using fine needle aspiration biopsy. *Otolaryngol Head Neck Surg* 2002;127:294-8.
- Only the references from journals indexed in PubMed will be checked.
- Enter each reference in new line, without a serial number.
- Add up to a maximum of 15 references at a time.
- If the reference is correct for its bibliographic elements and punctuations, it will be shown as CORRECT and a link to the correct article in PubMed will be given.
- If any of the bibliographic elements are missing, incorrect or extra (such as issue number), it will be shown as INCORRECT and link to possible articles in PubMed will be given.