

# Kshara application for turbinate hypertrophy

Vijay Kumar S. Kotrannavar, Savita S. Angadi<sup>1</sup>

Departments of Rasashastra, <sup>1</sup>Shalaky Tantra, KLE University's, Shri. B. M. Kankanawadi. Ayurveda Mahavidyalaya, Shahapur, Belgaum, Karnataka, India

## ABSTRACT

*Nasapratinaha* (nasal obstruction) is a commonly encountered disease in clinical practice. It is one of the nasal disorders, explained in Ayurveda, having nasal obstruction leading to difficulty in breathing as the main cardinal feature. In contemporary science, this condition can be correlated with various diseases such as turbinate hypertrophy, deviated nasal septum, nasal mass, mucosal congestion, allergic rhinitis, and others; among which turbinate hypertrophy is a common cause. Turbinate hypertrophy can be treated with surgical and medical methods. The medical treatment has limitation for prolonged use because of health purpose, surgical approaches too have failed to achieve desired results in turbinate hypertrophy due to complications and high recurrence rate. The medical and surgical managements have their own limitations, merits, and demerits like synechiae formation, rhinitis sicca, severe bleeding, or osteonecrosis of the turbinate bone. A parasurgical treatment explained in Ayurveda, known as *kshara pratisarana*, which is a minimal invasive and precise procedure for this ailment, tried to overcome this problem. '*Kshara Karma*' is a popular treatment modality in Ayurveda, which has been advocated in disorders of nose like *arbuda* (tumor) and *adhimamsa* (muscular growth). Clinical observation has shown its effectiveness in the management of turbinate hypertrophy. A case report of 45-year-old male who presented with complaints of frequent nasal obstruction, nasal discharge, discomfort in nose, and headache; and diagnosed as turbinate hypertrophy has been presented here. The patient was treated with one application of Kshara over the turbinates. The treatment was effective and no recurrence was noticed in the follow up.

**Key words:** Apamargakshara, *nasanaha*, *pratisarana*, turbinate hypertrophy

## INTRODUCTION

Nasal obstruction is a very common and troublesome complaint in ear, nose, and throat (ENT) practice. The main causative factor for this condition is turbinate hypertrophy. Other etiological factors involved are nasal allergy, vasomotor rhinitis, rhinitis medicamentosa, nasal mass, and deviated nasal septum. Hypertrophied turbinates are responsible for nasal obstruction more often than is

commonly thought. The inferior turbinates are the largest turbinates and are responsible for the majority of airflow direction, humidification, heating, and filtering of air inhaled through the nose. Allergies, exposure to environmental irritants, or a persistent inflammation within the sinuses can lead to turbinate swelling. Deformity of the nasal septum can also result in enlarged turbinates. Enlargement can be due to increase in soft tissues of turbinate or due to thickened bone. The medical management includes a variety of antihistamines, decongestants, and topical and systemic corticosteroids. These drugs provide only symptomatic improvement; they cannot cure the condition. They also can create side effects such as drowsiness, bleeding, drying, and crusting.<sup>[1]</sup> Among the many surgical procedures that have been used for the treatment of nasal obstruction are the trimming of the inferior turbinates, laser therapy, linear cautery, submucosal diathermy, and turbinate cryotherapy. All of them have been reported to be effective over the short-term, but they provide no sustained benefit.<sup>[2]</sup> Radiofrequency ablation (somnoplasty) and microdebridement of the turbinates are two of the newer techniques, but long-term data on their effectiveness are not yet available.<sup>[3]</sup> Thus a wide variety of surgical procedures have been performed on the turbinates for the relief of chronic nasal obstruction due to their hypertrophy, but the

### Address for correspondence:

Dr. Vijay Kumar S. Kotrannavar, Department of Rasashastra, KLEU's, Shri. B. M. K. Ayurveda Mahavidyalaya, Post Graduate Studies and Research Centre, Shahapur, Belgaum - 590 003, Karnataka, India.  
E-mail: kdrvijaykumar@yahoo.com

Received: 05-Apr-2013

Revised: 11-May-2013

Accepted: 05-Aug-2013

### Access this article online

Quick Response Code:



Website:

www.jaim.in

DOI:

10.4103/0975-9476.123722

results have been universally unsatisfactory. This condition is not fatal, however increased rapidly resulting in high rates of morbidity and has many adverse sequelae including mouth breathing, dryness of the oropharynx, nasal speech, disordered sleep, restlessness, malaise, an adverse effect on quality of life, and reduced lung volumes.<sup>[4,5]</sup>

As per ayurvedic classics, in *nasapratinaba* the vitiated kapha dosha along with vata dosha blocks the inspired air, leading to nasal obstruction. Based on the classical symptom it can be considered as one of the nasal obstructive lesion hypertrophied turbinate, in which there is enlargement of the sub mucosa and very rarely, the bone itself.<sup>[6]</sup> ‘*Kshara Karma*’ is a popular treatment modality in Ayurveda, which has been advocated in disorders of nose like *arbuda* (tumor) and *adhimamsa* (muscular growth)<sup>[7]</sup> besides many other diseases which are the results of unhealthy or undesirable growth of body tissues.<sup>[8]</sup> *Kshara* has properties of mainly *chbedan* (excision), *bbedhan* (incision), and *lekhan* (scraping),<sup>[9]</sup> and so serves the purpose of cutting, dividing, puncturing, scratching etc., moreover it is fit to be used in places where sharp instruments can be used with difficulty<sup>[10]</sup> like the nose. Hence considering this point it is assumed that the use of *ksharapratissarana* can be an effective solution in the management of *nasapratinaba* w.s.r. to turbinate hypertrophy. This case showed good results.

**CASE REPORT**

A 45-year-old male presented with the complaints of frequent nasal obstruction, nasal discharge, discomfort in nose, and headache since 3 years.

**On examination**

On local examination of the nose [Table 1] the external nose was normal with widened anterior nares. On anterior rhinoscopic examination, inferior turbinate in left side of the cavity was markedly hypertrophied with congestion of

the nasal mucous membrane [Figure 1]. In right side of the nasal cavity also there was mild hypertrophy of middle turbinate present. Routine hematology tests (hemoglobin, total count, differential count, erythrocyte sedimentation rate, and absolute eosinophil count) investigations were done. The erythrocyte sedimentation rate and absolute eosinophil count were slightly increased. Hemoglobin, total count, and differential count were within normal limits.

**Past history**

Patient had taken medical management which included a variety of antihistamines, decongestants, and topical and systemic corticosteroids since 3 years; but was of no use. After discontinuation of medication recurrence of the *nasanaba* was observed.

As the disease was not manageable with medical treatment and leading to complications like sleep apnea and mouth breathing, *kshara* application was selected in this case.

**Procedures administered to the patient**

**Purva Karma**

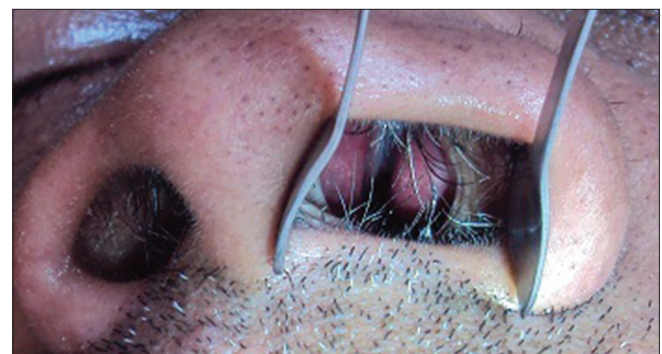
All the aseptic precautions were measured throughout the procedure. Patient was advised not to eat or drink anything (nil by mouth) for 4 h preceding the *ksharakarma* procedure. Ligno × 10% spray was sprayed into the left nostril to anesthetize the turbinate in order to avoid sneezing reflex and sensitivity. Patient was placed in supine position with the head extended by placing a pillow under the shoulders to expose the nasal cavity properly. A gauze piece soaked in lime water was placed into the left side of the nasal cavity away from the turbinate to avoid involvement of other normal structures.

**Pradhana Karma**

The left nasal cavity was exposed using Thudicum’s Nasal Speculum and a secretion over the turbinate was wiped out using gauze piece. *Apamargakshara* was applied over the medial surface of the exposed turbinate, by using the cotton rolled over Jobson probe. Applied *kshara* was kept for 2 min.<sup>[11]</sup> After sometime, the color changed to reddish

**Table 1: Local examination of nose**

External examination		
Shape	Normal	
Size	Normal	
Color	Light brown and no skin changes	
Nasal bridge	Straight	
Root of nose	Normal	
Anterior nares	Widened	
Internal examination		
Nasal cavity	Right side	Left side
Nasal mucosa	Congestion	Congestion
Turbinates	Hypertrophy of middle turbinate	Hypertrophy of inferior turbinate
Nasal septum	Mild deviation	-



**Figure 1: Before treatment**

brown (*Jambubhalavat*, i.e. the fruit of *Syzizium cumini* Linn.). The *kshara* was then removed with cotton rolled with Jobson probe. Lemon juice was applied over the turbinate to neutralize the remaining *kshara*. *Yastimadhu ghrita* was applied over the burnt wound to overcome *daha* (burning sensation).

### Paschat Karma

The patient was advised to avoid exposure to air or breeze, dust, smoke, etc., The patient was advised to take light diet.

### Follow-up

The patient was advised to follow-up for twice weekly for 15 days.

### RESULTS

Burning sensation was observed during and after the application of *kshara*, which was managed with local application of lemon juice for 15 min followed by nasal wash and after 30 min application of *Yashtimadhu ghrita*. The patient was complained of dark brown colored watery discharge on the next day which was self-controlled, in 4 days. The complete reduction in the size of hypertrophied turbinate was observed on the next day [Figure 2]. Along with nasal obstruction the other associated complaints, like nasal discharge, discomfort in nose, and headache were completely reduced within 1 week. After 1 week, once again the blood investigations (erythrocyte sedimentation rate and absolute eosinophil count) were done, which were found to be within normal limits. The patient was advised to avoid exposure to cold wind, dust, intake of cold items, etc., which are considered as *pratishyaya* (rhinitis) causative factors. With a follow-up for a period of 6 months, the patient had not got even a single time nasal obstruction and other symptoms. Meanwhile, he was prescribed oral medication viz., *Sitopaladi churna*, *Talisadi churna* along with *Hareetaki churna* [2:2:1/2 proportion] one teaspoon twice daily for 1 month with lukewarm water.

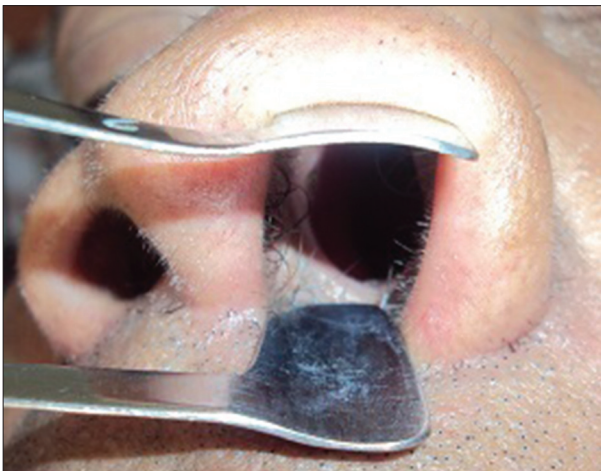


Figure 2: After treatment

### DISCUSSION

Nasal cavities provide conduction, filtration, heating, humidification, and chemosensation of air which is mainly performed through mucosa and contours of the turbinates. The turbinates undergo cyclical increase and decrease in their size as part of the nasal cycle. Both allergic and nonallergic rhinitis can lead to pathological, persistent increase in turbinate size. This often causes a marked restriction in airflow through the valve region with a concomitant sensation of severe nasal blockage.<sup>[12]</sup> Hence, nasal obstruction by turbinate hypertrophy causes significant difficulty affecting the daily activities of the patients. Nasal obstruction in chronic nonallergic or hypertrophic rhinitis is usually caused by submucosal or mucosal hypertrophy and boggy tissue due to increased vascularity as anterior end of the inferior turbinate is erectile tissue.<sup>[13]</sup> The inflammatory response or inflammation is an important body response to injury. When bacteria, toxins, burns, or other culprits damage tissue; the injured tissues leak chemicals, including histamine and other substances. This chemical cocktail causes blood vessels around the damaged area to leak fluid into the injured tissues and make them swell. Here, the enlargement of turbinate is almost always due to swelling of the submucosa and mucosa. Thus, this increase in turbinate size as well as submucosal or mucosal hypertrophy can be taken as *adbimamsa* and according Acharya Charaka, the line of treatment for *arbuda* (tumor), *adhimamsa* (extra muscular growth) is *kshara* application. Hence, *ksharapratisarana* was selected for the treatment.

Local application of *kshara* acts on hypertrophied turbinate in two ways:

- It cauterizes hypertrophied mass directly because of its corrosive nature. Thus, produces shrinking effect on hypertrophied tissue
- It penetrates in to the boggy tissue which is produced due to increased vascularity, as anterior end of the inferior turbinate is erectile tissue and coagulates protein in increased vascularity. The coagulation of protein leads to disintegration of hemoglobin into heme and globin. Synergy of these actions results in decreasing the size of the turbinate hypertrophy. Further, necrosis of the tissue occurs. This necrosed tissue sloughs out as blackish brown discharge for 3-7 days. The submucosal or mucosal hypertrophy and boggy tissue obliterates permanently and there was no recurrence of turbinate hypertrophy.

### CONCLUSION

There are certain methods of using *kshara*. One of them is application of *kshara*, which has been proved very effective in the treatment of unhealthy or undesirable growth of

body tissues, and is being practiced widely. In this present case report, *apamarga* (*Achyranthus aspera* Linn.) *kshara*, one among the best *ksharas*, was locally applied on the hypertrophied turbinate to find out its efficacy and adverse effects. It has given excellent results in the treatment of turbinate hypertrophy. This effectiveness of *kshara* application can be attributed only to the potency of the particular content. *kshara* application is the best one, taking into the consideration of its convenience, easy adoptability, cost-effectiveness, and curative results. Accordingly, the *Apamarga kshara* is said to be very useful in treating the turbinate hypertrophy locally.

## REFERENCES

- Powell NB, Zonato AI, Weaver EM, Li K, Troell R, Riley RW, *et al.* Radiofrequency treatment of turbinate hypertrophy in subjects using continuous positive airway pressure: A randomized, double blind, placebo-controlled clinical pilot trial. *Laryngoscope* 2001;111:1783-90.
- Warwick-Brown NP, Marks NJ. Turbinate surgery: How effective is it? A long-term assessment. *ORL J Otorhinolaryngol Relat Spec* 1987;49:314-20.
- Grymer LF, Illum P, Hilberg O. Septoplasty and compensatory inferior turbinate hypertrophy: A randomized study evaluated by acoustic rhinometry. *J Laryngol Otol* 1993;107:413-7.
- Willatt D. The evidence for reducing inferior turbinate's. *Rhinology* 2009;47:227-36.
- Mathai J. Inferior turbinectomy for nasal obstruction review of 75 cases. *Indian J Otolaryngol Head Neck Surg* 2004;56:23-6.
- Scott-Brown. In: Mackay, Bull, Editors. *Otolaryngology*. 6<sup>th</sup> ed. 9<sup>th</sup> Chapter. Oxford: Butterworth-heinemann; 1997; p. 10.
- Agnivesha; Charak Samhita, 'Ayurveda-Dipika' Commentary of Cakrapanidatta. In: Vaidya Jadavji Trikamji Acharya, editor. *Chikitsasthana*. 26<sup>th</sup> Chapter, 157<sup>th</sup> Sloka. Varanasi: Chowkhamba Krishnadas Academy; 2006. p. 607.
- Vaidya Jadavji Trikamji Acharya. *Sushruta Samhita of Susruta, 'Nibandha Sanghaha' Commentary of Sri Dalhanacharya and 'Nyayachandrika Panjika' of Sri Gayadasacharya on Nidansthana; Sutrasthana, 11<sup>th</sup> Chapter, 7<sup>th</sup> Sloka*. Varanasi: Chowkhamba Krishnadas Academy; 2004. p. 46.
- Sushruta; Sushruta Samhita, 'Ayurveda Tatva Sandipika', Dr. Ambikadatta Shastri, Sutra sthan-11/5, Varanasi: Chawkhamba Sanskrit Sansthan; 2001. p. 34.
- Sharma S. editor, *Astanga Samgraha of Vagbhata; with 'Sasilekha' Commentary by Indu; Sutrasthana- 39/1,21- 1<sup>st</sup> ed.* Varanasi: Chowkhamba Canskrit Series Office; 2006. p. 260.
- Dr. Ambikadatta Shastri, *Sushruta Samhita of Sushruta, Ayurved Tatva Sandipika; Sutra sthan*. Varanasi: Chaumbika Sanskrit Sansthan; 2001. p. 36.
- Dr.Kassim R.Dekhil, Prevalence of early complications of partial inferior turbinectomy, *Kufa Med. Journal* 2011. Vol. 14.No. 1, 231.
- Taneja M, Taneja MK. Intra turbinate diathermy cautery V/S high frequency in inferior turbinate hypertrophy. *Indian J Otolaryngol Head Neck Surg* 2010;62 (3) (Rhinology):317-21.

**How to cite this article:** Kotrannavar VK, Angadi SS. Kshara application for turbinate hypertrophy. *J Ayurveda Integr Med* 2013;4:241-4.

**Source of Support:** Nil, **Conflict of Interest:** None declared.

## Announcement

### Android App



Download  
**Android  
application**

FREE

A free application to browse and search the journal's content is now available for Android based mobiles and devices. The application provides "Table of Contents" of the latest issues, which are stored on the device for future offline browsing. Internet connection is required to access the back issues and search facility. The application is compatible with all the versions of Android. The application can be downloaded from <https://market.android.com/details?id=comm.app.medknow>. For suggestions and comments do write back to us.