



Case Report

Effect of Ayurveda interventions in non-alcoholic grade II fatty liver associated with obesity – A case report



A.K. Sahu, A. Upadhyay, H. Bhakuni, A.M.H.S. Attanayake*, P. Sharma

PG Department of Kayachikitsa, National Institute of Ayurveda, Jorawar Singh Gate, Amer Road, Jaipur, Rajasthan, India

ARTICLE INFO

Article history:

Received 16 April 2022

Received in revised form

4 June 2022

Accepted 6 June 2022

Available online xxx

Keywords:

Ayurveda treatment

Obesity

Fatty liver

ABSTRACT

Fatty Liver, one of the most common liver diseases worldwide, usually emerges due to lipid accumulation, mostly triglycerides in hepatocytes. Fat exists in the liver naturally, but if it surpasses 5–10% of the liver's total weight, it can result in fatty liver. In this case, report effect of Ayurveda intervention in grade II fatty liver is reported. Thirty-five-year-old obese male with grade II fatty liver presented with fatigue, abdominal pain, heaviness, and incomplete bowel evacuation to the National Institute of Ayurveda hospital, Jaipur, Rajasthan, India. On examination, there was no significant clinical abnormality except a high body mass index (BMI = 30.2). Hematological examinations revealed altered Alanine transaminase, fasting blood glucose, total cholesterol, low-density lipoprotein, and triglycerides. The patient was diagnosed sonologically with a grade II fatty liver. The patient was given Ayurveda treatment for two months with three treatment regimens. The patient was assessed for improvement in signs and symptoms, hematological parameters, and quality of life using a chronic liver disease questionnaire (CLDQ). After two months, significant improvement was observed in signs and symptoms, BMI (24.7), and CLDQ. No fatty tissue was reported sonologically, and all altered biochemical parameters were within normal limits. Present case highlights the potential of Ayurveda interventions in managing non-alcoholic fatty liver disease and obesity.

© 2022 The Authors. Published by Elsevier B.V. on behalf of Institute of Transdisciplinary Health Sciences and Technology and World Ayurveda Foundation. This is an open access article under the CC BY-NC-ND license (<http://creativecommons.org/licenses/by-nc-nd/4.0/>).

1. Introduction

Non-alcoholic fatty liver disease (NAFLD) consists of steatosis and non-alcoholic steatohepatitis (NASH). Steatosis is the accumulation of fat in the liver, and steatohepatitis is a condition with inflammation [1]. NAFLD is a growing epidemic worldwide due to increasing obesity, with prevalence in the general population ranging from 11.2% to 37.2% [2]. Among obese patients, the frequency of NASH ranges from 12.6% to 30.4% [3]. Worldwide, NAFLD cases have increased from 19.34 million to 29.49 million from 1990 to 2017. The greatest burden is in East Asia, followed by South Asia, North Africa, and the Middle East [4].

In Ayurveda, NAFLD is assigned as *Yakrit Roga* (liver disease) and *Medoroga* (obesity) [5] (5. Sutra 21/4). Many conditions come under *Yakrit Roga*, varying from simple steatosis to hepatomegaly to liver cirrhosis. The ancient text of *Yogratnakara* described that Vidahi

(spicy food) and *Abhisyandi Ahara* (food that blocks the channels) lead to *Rakta-Kapha Dushti* giving rise to *Yakritodara* (enlargement of the liver). This case report highlights the treatment effects of Ayurveda interventions in a patient with grade II NAFLD. <http://www.care-statement.org>

2. Case report

A 35 year-old non-alcoholic, unmarried male patient, relatively obese (BMI = 30.2) from an urban area, came for Ayurveda treatment at our hospital. The patient was 6 feet tall, weighing 90 kg, and looking unwell and tired. The patient mainly complained about fatigue, anorexia, body pain, incomplete bowel evacuation, and abdominal distension. These symptoms have been persisting in the patient for the past 6 months.

2.1. Clinical findings

At the presentation time, the patient's pulse rate was 82/min, blood pressure was 130/80 mmHg, and respiratory rate was 15/min.

* Corresponding author.

E-mail: harshamed@yahoo.com

Peer review under responsibility of Transdisciplinary University, Bangalore.

The body temperature was normal. No abnormal clinical finding for cardiovascular and respiratory systems was observed on examination. His abdomen was distended due to fat and was normally moving with respiration. On palpation, mild tenderness was found in the right lumbar and umbilical regions. Dull sounds were recorded during the percussion on the right lumbar region, and bowel sounds were normal on auscultation. No relevant family, medical and surgical, or psychological illness history was present in the patient. The patient had consulted for similar medical complaints with an allopathic physician 6 months back. Antacids and laxatives were given to control the abdominal distension and bowel evacuation. During this period patient was not recovered completely and due to the reoccurrence of symptoms seek, he for Ayurveda treatment. He was presently not on any medication while the Ayurvedic intervention was ongoing.

2.2. Diagnosis

The patient was referred to a sonologist for ultrasonography of the whole abdomen, and the patient was found to be having grade II fatty liver (Fig. 1a.). No other abnormal sonographic finding was reported. The patient was thus diagnosed with grade II NAFLD with obesity. The Ayurvedic diagnosis was *Yakrit Roga* (liver disease), associated with *Medoroga* (obesity).

2.3. Intervention

The patient was given Ayurvedic medication for 60 days. All the interventions are presented in Table 1.

2.4. Diet

No specific diet or exercise schedule was given to the patient during the treatment period of two months.

3. Timeline of treatment:

The patient had treatment for three months. The timeline of the treatment is presented in Table 2.

4. Results

4.1. Observations

The patient was observed for improvement in symptoms related to *Yakrit Roga* and *Medo Roga* on the four-point grading system (none, mild, moderate, and severe). Details of the recorded observations are presented in Table 3.

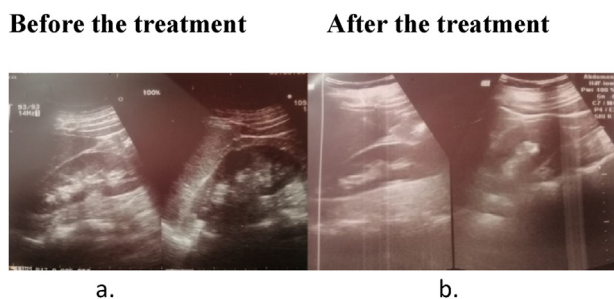


Fig. 1. a – USG before the treatment, b – USG after the treatment.

4.2. Quality of life

Quality of life assessment was done using the chronic liver disease questionnaire (CLDQ) [8]. The evaluation was done on day 1, day 15, day 30, and day 60. Data are presented in Table 4.

Before initiating the treatment, the total quality of life score was 118 out of 203, which improved to 190 over 203 (35.4%). After 60 days of treatment, more than 50% improvement was observed in abdominal symptoms and fatigue.

4.3. Patient perspective

The patient was satisfied with the treatment given and the improvement in his digestion, appetite, bowel evacuation, lethargic condition, and weight reduction. After two months of the treatment, the patient was feeling energetic, and actively doing his daily activities.

5. Effect on biochemical parameters

Biochemical parameters were assessed before starting the treatment and after two months. Data is presented in Table 5.

After two months of Ayurveda interventions, significant improvement was observed in all the laboratory parameters, and they were in the normal range. However, the effect was more pronounced on Alanine transaminase, total cholesterol, low-density lipoprotein, and triglyceride levels.

6. Ultrasonography of the whole abdomen (USG)

Before treatment, the liver was bright and echogenic, and the portal venous radicle's echogenicity was also lost (Fig. 1a). After two months, there was a complete remission of the lesion in the liver parenchyma. In addition, intrahepatic biliary radicals and portal vein radicals showed no abnormalities after two months of treatment (Fig. 1b).

7. Discussion

Fatty liver is commonly encountered in routine clinical practice. The majority of the cases do not suffer much, but some may progress to steatosis, steatohepatitis, and fibrosis. In some cases, it may develop hepatocellular carcinoma. Fatty liver is the common cause of the liver dysfunction, and compared to alcoholic fatty liver, few cases of NAFLD seem to develop chronic liver disease [9]. In this study, we have treated a non-alcoholic, obese patient who had grade II fatty liver. According to Ayurveda, *Santarpana* (overeating and sedentary lifestyle) is responsible for the vitiation of *Kapha* and *Meda*, which are the main *Dosha* and *Dushya* involved in the pathogenesis of *Sthaulya* (obesity) [10]. Our practice shows that persons with vitiated *Kapha* and *Meda* (fat) are prone to develop fatty liver and altered lipid profiles. A similar clinical picture was observed in the present case. *Agni Deepana* (enhancing the digestive fire), *Ama Pacana* (eliminating the toxins from the body), and *Virechana* (laxative) were the main principles applied in this case (5. Sutrasthana 21/5-9). Most of the ingredients of *Avipattikara Churna* have *Ama Pacana* (eliminating the toxins from the body), *Mriduvirechaka* (mild laxative), and *Lekhaniya* (which scrapes excess fats) properties (5. Sutrasthana 21/21) (5. Sutrasthana 4/8-9). Powder of *Pichrorhiza kurroa Royle ex Benth.* having *Tikta Rasa Pradhana* is also helpful in *Ama Pacana* (eliminating the toxins from the body) and *Lekhaniya* (which scrapes the excess fat) [11,12]. *Pichrorhiza kurroa Royle ex. Benth.* has shown potent hepatoprotective and immune-modulatory properties [13]. Ingredients of *Avipattikara Churna* and *Punarnava Mandura* have digestive, hepatoprotective, metabolism-enhancing, and antioxidant

Table 1
Therapeutic interventions [6,7] (5. Sutra 21/21-22) (5. Chi 16/93-96).

Treatment regimen	Duration	Drug	Dose and frequency	Route of administration
One	Day 1–15	<i>Avipattikara Churna</i>	3 g twice a day	Oral
		<i>Punarnava Mandoor</i>	250 mg twice a day	Oral
		<i>Sankha Bhasma</i>	250 mg twice a day	Oral
		<i>Tarunikusumakara Churna</i>	3 g once a day at bedtime	Oral
Two	Day 16–30	<i>Avipattikara Churna</i>	3 g twice a day	Oral
		<i>Punarnava Mandoor</i>	250 mg twice a day	Oral
		<i>Sankha Bhasma</i>	250 mg twice a day	Oral
		<i>Triphala Churna</i>	3 g once a day at bedtime	Oral
Three	Day 31–60	<i>Avipattikara Churna</i>	3 g twice a day	Oral
		<i>Punarnava Mandoor</i>	250 mg twice a day	Oral
		<i>Sankha Bhasma</i>	250 mg twice a day	Oral
		<i>Kutki Churna</i>	1 g once a day at bedtime	Oral

Table 2
Timeline of the treatment.

Health event	Timeline
First USG of the abdomen and diagnosis of grade II fatty liver	2021 August 07
Approached for Ayurveda treatment	2021 August 08
Assessment and examination were done. The treatment regimen first started	2021 August 09
Assessment on first follow-up and treatment regimen two started	2021 August 24
Assessment on second follow-up and treatment regimen three started	2021 September 08
Assessment of third follow-up and follow-up USG abdomen was advised	2021 October 08

Table 3
Observation of Signs and symptoms related to liver and obesity.

Parameter	Day 1	Day 15	Day 30	Day 60
Yakrit Roga related signs and symptoms				
<i>Udarshoola</i> (pain in the abdomen)	Mild	None	None	None
<i>Utkleśha</i> (feeling of nausea and vomiting)	Severe	Mild	None	None
<i>Aruchi</i> (loss of appetite)	Severe	Mild	None	None
<i>Hṛitkaṇṭhadāha</i> (heartburn)	Severe	Moderate	Mild	None
Height, weight, and BMI				
<i>Height (feet)</i>	6	6	6	6
<i>Weight (kg)</i>	98	94	88	80
<i>Body Mass Index (BMI)</i>	30.2	29	27.2	24.7
Obesity-related signs and symptoms				
<i>Ayusho Hrasa</i> (deficient in longevity)	Severe	Moderate	Mild	None
<i>Javoparadha</i> (Slow in movement)	Severe	Moderate	Mild	Mild
<i>Krichchavyavaya</i> (difficult to indulge in sexual intercourse)	Severe	Moderate	Mild	None
<i>Daurbalyam</i> (weak)	Severe	Moderate	Mild	No
<i>Daugandhya</i> (Bad smell)	None	None	None	None
<i>Swedabadha</i> (much sweating)	None	None	None	None
<i>Ati Kshudha</i> (excessive hunger)	Severe	Mild	None	None
<i>Ati Pipasa</i> (excessive thirst)	Severe	Moderate	Mild	None

Table 4
Assessment of quality of life.

Parameter	Day 1	Day 15	Day 30	Day 60	Improvement %
Abdominal symptoms (3)	4/21	13/21	17/21	20/21	76.2
Fatigue (5)	7/35	12/35	20/35	30/35	65.7
Systemic symptoms (5)	26/35	28/35	30/35	33/35	20
Activity (3)	12/21	18/21	21/21	21/21	43
Emotional function (8)	42/56	48/56	50/56	52/56	18
Worry (5)	27/35	29/35	30/35	34/35	20
Total (29)	118/203	148/203	168/203	190/203	35.4

properties. In this case, improved digestion and metabolism were observed within a few days of initiating the treatment, which probably improved biochemical parameters related to liver functions and lipid metabolism [14–16]. A daily laxative was also prescribed to ease the expulsion of solid water from the colon. Daily purgation is also an important line of treatment in managing *Udara*

Roga (abdomen-related disorders). The beneficial effects of satisfactory bowel evacuations were observed in the present case. Further, sonographic evidence, showed a reduction in fat deposited in the liver and periportal area. These findings highlights the usefulness of prescribed treatment in managing obesity and non-alcoholic fatty liver conditions.

Table 5
Effect of treatment on Biochemical parameters.

Parameter	Day 1	Day 60	% Improvement
Aspartate aminotransferase (U/L)	30	29	3.3
Alanine transaminase (U/L)	66	50	24.2
Fasting blood glucose (mg/dl)	115	75	34.7
Total cholesterol (mg/dl)	255	191	25.1
High density lipoprotein (mg/dl)	53	57	7.5
Low density lipoprotein (mg/dl)	185	117	36.7
Triglycerides (mg/dl)	180	84	53.3
Serum gamma-glutamyl transferase (IU/L)	22	21	4.5
Serum amylase (U/L)	70	65	7.1

8. Conclusion

On the basis of the results, we can conclude that Ayurvedic interventions used in the present case have shown a significant effect on weight reduction and management of non-alcoholic fatty liver. The results observed in this case are encouraging, and further well-designed clinical trials may be carried out to test the efficacy of these interventions in similar conditions.

Informed consent

Informed consent for the publication of the data was taken from the patient.

Funding sources

Nil.

Authors contribution

Concept; AK Sahu. Design; AK Sahu, A Upadhyay, H Bhakuni, AMHS Attanayake, P Sharma. Manuscript Preparation; AK Sahu, A Upadhyay, H Bhakuni, AMHS. Attanayake. Manuscript editing; A Upadhyay, AMHS. Attanayake. Manuscript review; Guarantee. Other; AK Sahu, A Upadhyay, AMHS Attanayake.

Abbreviations

NAFLD	non-alcoholic fatty liver disease
NASH	non-alcoholic steatohepatitis
BMI	body mass index
USG	ultrasonography

References

- [1] Huang DQ, El-Serag HB, Loomba R. Global epidemiology of NAFLD-related HCC: trends, predictions, risk factors and prevention. *Nat Rev Gastroenterol Hepatol* 2021;18(4):223–38. <https://doi.org/10.1038/s41575-020-00381-6>.
- [2] Benedict M, Zhang X. Nonalcoholic fatty liver disease: an expanded review. *World J Hepatol* 2017;9(16):715–32. <https://doi.org/10.4254/wjh.v9.i16.715>.
- [3] Younossi ZM, Koenig AB, Abdelatif D, Fazel Y, Henry L, Wymer M. Global epidemiology of non-alcoholic fatty liver disease—meta-analytic assessment of prevalence, incidence, and outcomes. *Hepatology* 2016;64:73–84. <https://doi.org/10.1002/hep.28431>.
- [4] Zhang X, Wu M, Liu Z, Yuan H, Wu X, Shi T, et al. Increasing prevalence of NAFLD/NASH among children, adolescents and young adults from 1990 to 2017: a population-based observational study. *BMJ Open* 2021;11(5):e042843. <https://doi.org/10.1136/bmjopen-2020-042843>.
- [5] Sharma RK, Dash B, editors. *Charaka Samhita text with English translation and critical exposition based on Cakrapani Datta's Ayurveda Dipika*. 1st ed. Varanasi: Chowkhamba Sanskrit Series Office; 2019.
- [6] Chapter 56, Verse 25-29. In: Mishra SB, editor. *Bhashajayarathnavali of Sri Govinda Dasji*. 1st ed., vol. III. Varanasi: Chaukhambha Sanskrit Sansthan publishers; 2017. p. 117.
- [7] Murthy PHC. Chapter 4, Verse 3-4. *Sarangadara Samhita of Sarangadhara-acarya*. 1st ed., vol. 33. Varanasi: Chowkhamba Sanskrit Series office; 2018.
- [8] Dam-Larsen S, Franzmann M, Andersen IB, Christoffersen P, Jensen LB, Sørensen TI, et al. Long term prognosis of fatty liver: risk of chronic liver disease and death. *Gut* 2004;53(5):750–5. <https://doi.org/10.1136/gut.2003.019984>.
- [9] Younossi ZM, Guyatt G, Kiwi M, Boparai N, King D. Development of a disease-specific questionnaire to measure health-related quality of life in patients with chronic liver disease. *Gut* 1999;45:295–300. <https://doi.org/10.1136/gut.45.2.295>.
- [10] Singhal P, Nesari T, Gupta GS. Efficacy of herbo-mineral compounds and pathya (Ayurvedic dietary regime and physical exercise) in the management of Yakrt Roga (Non-alcoholic fatty liver disease). *Anc Sci Life* 2015;34(4):216–22. <https://doi.org/10.4103/0257-7941.160866>.
- [11] Sastry JLN. *Illustrated Dravyaguna Vijnana (study of the essential medical plants in Ayurveda)*, vol. 2. Varanasi: Chaukhambha Orientalia; 2017. p. 391.
- [12] Tarapore S, Tubaki BR, Khot S. Elastographic liver evaluation of Katukyadi churna in the management of Non-Alcoholic Steatohepatitis (NASH) – a single arm clinical trial. *J Ayurveda Integr Med* 2021;12(1):136–42. <https://doi.org/10.1016/j.jaim>.
- [13] Verma PC, Basu V, Gupta V, Saxena G, Rahman LU. Pharmacology and chemistry of a potent hepatoprotective compound Picroliv isolated from the roots and rhizomes of *Picrorhiza kurroa royle ex benth.* (kutki). *Curr Pharm Biotechnol* 2009 Sep;10(6):641–9. <https://doi.org/10.2174/138920109789069314>.
- [14] Pandya MG, Dave AR. A clinical study of Punarnava Mandura in the management of Pandu Roga in old age (geriatric anemia). *Ayu* 2014;35(3):252–60. <https://doi.org/10.4103/0974-8520.153735>.
- [15] Rawat AK, Mehrotra S, Tripathi SC, Shome U. Hepatoprotective activity of *Boerhaavia diffusa* L. roots – a popular Indian ethnomedicine. *J Ethnopharmacol* 1997 Mar;56(1):61–6. [https://doi.org/10.1016/s0378-8741\(96\)01507-3](https://doi.org/10.1016/s0378-8741(96)01507-3).
- [16] Wei X, Luo C, He Y, Huang H, Ran F, Liao W, et al. Hepatoprotective effects of different extracts from *Triphala* against CCl₄-induced acute liver injury in mice. *Front Pharmacol* 2021;12:664607. <https://doi.org/10.3389/fphar>.