



Case Report

An integrated management (Ayurveda and Modern medicine) of accidental burn injury: A case study

Pradeep S. Shindhe^{*}, Priyanka K, Ramesh S. Killedar, Dhruvnu Prasannan, Kirthi A

Dept of Shalya Tantra, KAHER'S Shri B M Kankanawadi Ayurveda Mahavidyalaya, Shahapur, Belagavi, Karnataka, India

ARTICLE INFO

Article history:

Received 8 March 2022

Received in revised form

4 November 2022

Accepted 18 January 2023

Available online xxx

Keywords:

Accidental burn

Total body surface area

Ropana ghrita

Patraadaana

Dhoopana

ABSTRACT

Burn injuries are frequent, horrifying, and life-threatening conditions that are still challenging to cure. Complications like scarring, keloid formation, and contractures are the main challenges for the treating surgeon. The Ayurvedic classics explain different treatment modalities for the management of burn wounds, like oral medicines, topical applications prepared with herbal medicines, ghee, oil, and typical wound dressing techniques like *Patraadaana* (wound covering with medicinal leaves), and fumigation therapy, etc. Here we report a case of accidental burn injury with a TBSA of 27% First degree (superficial) and 15% second degree (deep partial-thickness) burns with complaints of fever and burning sensation at the burn site. On the basis of the symptoms listed in the classical texts of Ayurveda, the case was diagnosed as *Pramadadagdha* (accidental burn). To properly manage the burn wound, an integrated therapy strategy was designed. *Ropanaghrta* (medicated ghee) was applied locally, followed by the application of *Tinospora cordifolia* leaves to cover the wound, fumigation therapy, and oral medications to hasten wound healing and reduce infection. In the first seven days, modern medicine was used as emergency care in addition to Ayurvedic management. Within 60 days of receiving treatment, the burn wound had entirely healed, and the patient was able to resume her regular work activities. In the current situation, the combined strategy produced encouraging burn management outcomes.

© 2023 The Authors. Published by Elsevier B.V. on behalf of Institute of Transdisciplinary Health Sciences and Technology and World Ayurveda Foundation. This is an open access article under the CC BY-NC-ND license (<http://creativecommons.org/licenses/by-nc-nd/4.0/>).

1. Introduction

Burn injuries can occur from fire, moist heat, electrical source, chemical agents, radiations, etc [1]. In India, an estimated [6,7] million cases of mild to severe burns are reported each year [2,3]. Burn injuries are typically 86% thermal in origin, 4% electrical, and 3% chemical in nature. Burn injuries are more common in low- and middle-income people [4]. Standard guidelines for managing burns include fluid resuscitation, airway preservation, analgesics, broad-spectrum antibiotics, nutritional support, escharotomy, fasciotomy, skin grafting, and tetanus prophylaxis [5]. Topical applications, such as silver sulfadiazine, silver nitrate gel/solution, and fusidic acid, form the foundation of burn wound care. Dermatitis, renal failure, wound infection, and pneumonia are early complications, while scarring and contractures are late complications [6]

Even after overcoming these early complications of burns with the utmost emergency care, the late complications remain. Acute respiratory distress syndrome and septicemia are the most challenging aspects of treating burn cases.

Burn injuries are discussed under *Dagdhavrana* in Ayurveda. The classification of burn injuries and treatment by *Acharya Susruta* can be closely related to the degree of burn in modern science, with terms like *Plushta* (first-degree burn), *Durdagdha* (second-degree partial thickness burn), *Samyakdagdha* (second-degree full-thickness burns), and *Atidagdha* (third-degree burn, involving muscle and joints) [7]. Sixty therapeutic procedures are explained in the Ayurvedic classics for the management of wounds. Dressing of the burn wound with medicated ghee preparations and bandaging with *Tinospora cordifolia* leaves, as well as wound fumigation with medicinal drugs, were important treatments considered under local wound care [8]. Oral medicines like *triphala guggulu*, *punernava mandoor*, *punernavadi kashaya*, etc. were advised in the management of various symptoms of burn wounds.

Abbreviations: TBSA, Total body surface area.

* Corresponding author.

E-mail: pshindhe@gmail.com

Peer review under responsibility of Transdisciplinary University, Bangalore.

<https://doi.org/10.1016/j.jaim.2023.100691>

0975-9476/© 2023 The Authors. Published by Elsevier B.V. on behalf of Institute of Transdisciplinary Health Sciences and Technology and World Ayurveda Foundation. This is an open access article under the CC BY-NC-ND license (<http://creativecommons.org/licenses/by-nc-nd/4.0/>).

Here, we report a case of accidental burn injury which was managed effectively with integrated approach, i.e., Ayurvedic and modern medicine treatment principles.

2. Patient information and clinical findings

A 44-year-old female presented with burns over: the whole of the posterior side of the right arm; the whole right forearm with hand; more than two-thirds of the back; the right lateral sides of the chest and abdomen; part of the lower chest and upper abdomen over the anterior trunk; and the posterior and lateral areas of the right thigh with the right hip (Fig. 1 and 2).

The incident was caused by the flame from a gas explosion while cooking. For five days, the patient was treated conservatively at an Modern medicine hospital, receiving intravenous antibiotics and anti-inflammatory drugs as well as wound care (application of Silverex ointment) (Table 1). She was discharged as her complaints had subsided and was advised to rest at home. She approached our hospital as symptoms like fever and intense pain at the burn site were aggravated due to a lack of definitive care and negligence by the patient. The general examination revealed that she was moderately built and well-nourished. The systemic examination revealed that she was conscious, well-oriented, and without any co-morbidities. Her vital signs showed a pulse rate of 108 beats per minute, blood pressure of 100/70 mm of Hg, a respiratory rate of 24 per minute, and a body temperature of 99.8 °F. The local examination revealed second-degree partial-thickness burns on the posterior side of the right arm (centre with red, white, and eschar) and first-degree burns (periphery with pink color) over the right forearm and hand. Second-degree partial-thickness burns (red, white, and eschar) were seen over the scapular region and first-degree burns (pink color) on more than two-thirds of the back. Second-degree partial-thickness burns were seen from the right

axillary region to the right hip, which are second-degree partial-thickness burns seen on the lower chest and upper abdomen over the anterior trunk. A second-degree partial-thickness burn was seen in the posterior and lateral areas of the right thigh. The haematology and urine reports revealed haemoglobin of 9.2 gm%, WBC count of 13,700 cells/cumm, Neutrophils - 58%, Lymphocytes - 28%, Eosinophil - 12%, and Monocytes - 2%, ESR of 160 mm/hr, Platelet count of 428,000 cells/cumm, BT - 3 min, CT - 6 min, RBS 184 mg/dl, blood urea 18 mg/dl, serum creatinine 0.9 mg/dl, and RBC count of 3.57 million/cumm. The patient was catheterized to observe the urine output.

2.1. Diagnosis

The diagnosis was established based on the signs, symptoms, and clinical examination. It was diagnosed as an accidental burn injury with a TBSA of 27% for the first degree (superficial with a pink colour appearance) and 15% for the second degree (deep partial-thickness burn with eschar) burn. In *Ayurveda*, it was diagnosed as *Plushta* and *Durdagdha*, and treatment was planned accordingly.

2.2. Therapeutic intervention

The treatment protocol was designed with an integrated approach, i.e., Modern medicine and *Ayurveda*. The prognosis and probable complications, risks were informed to the patient and their relatives; later, treatment was initiated after obtaining high-risk consent. The patient was initially treated by a modern medicine specialist with standard treatments like fluid therapy, intravenous antibiotics, and anti-inflammatory drugs. According to the "4-2-1" fluid replacement rule, the fluid requirement was 2400 ml. As the patient was taking fluids orally (1500 ml), a

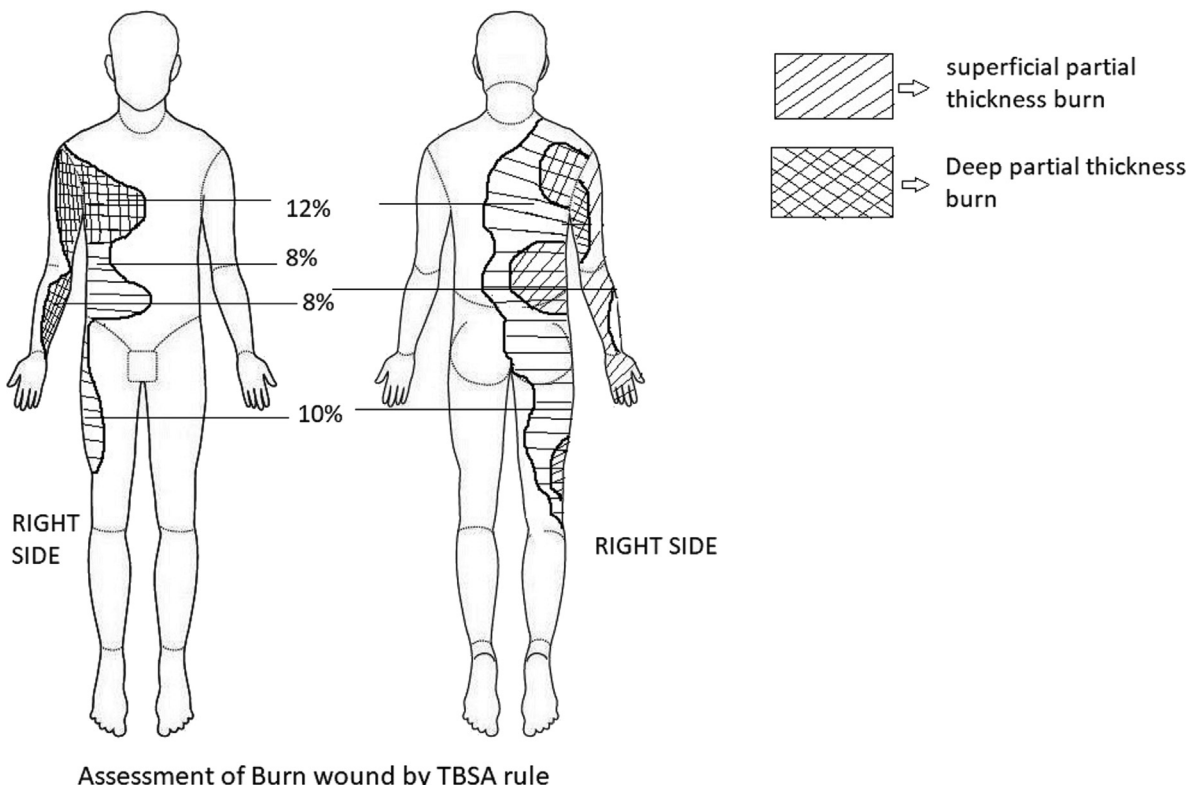


Fig. 1. Assessment of burn wound.

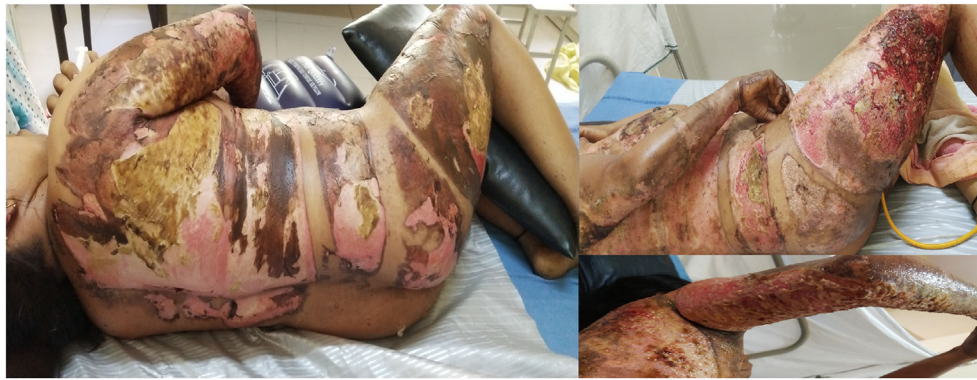

Fig. 2. Initial stage(A)(B)(C).

Table 1

Time line

25/03/2021	Patient met with accidental burn injury and received emergency care in modern hospital.
1/4/2021	Symptoms aggravated due to lack of definitive care and negligence by the patient.
04/04/2021 to 31/05/2021	Integrated approach (Ayurveda and Modern medicine) was initiated and patient responded well with treatment.

900 ml fluid deficit was present, and it was substituted by 1000 ml of crystalloids (900 ml replacement + 100 ml to overcome insensible loss) [9].

Local burn wound care was done with *ropana ghrita* application over the burn site followed by bandaging with *T. cordifolia leaves* (Fig. 3) twice daily. As a measure for infection control, fumigation was done twice daily at the burn site and the patient's room with powders of medicinal drugs like *Commifora mukul*, Neem leaves, etc. The therapeutic interventions and oral medications are highlighted in Table 2 and the assessment of wound healing (with the "Bates-Jensen wound assessment tool") are shown in Table 3 [10].

2.3. Follow up and outcome

The patient was admitted for a period of 25 days and advised to continue the same oral medications after discharge, along with the *Ropana ghrita* application. The drugs for fumigation were given to the patient and she was instructed to continue at home. The patient was advised to perform the movements of affected joints in order to prevent contracture and asked to visit the hospital every 10th day for assessing the changes in the wound. The wound healed

completely (Fig. 4) with mild contracture (at the wrist joint, elbow joint, and axilla, where the second-degree partial-thickness burns were present) after 60 days of treatment. The patient is now able to perform her routine activities without any discomfort.

3. Discussion

Burn injury management is a difficult task as it causes significant pain and disability to the victims. These injuries requires proper wound care as they are more susceptible to infection. Long-term heat/temperature exposure causes tissue damage and protein denaturation, resulting in the release of toxic metabolites that cause localized oedema and a systemic inflammatory response [11]. The prime concern in burn injury management is late complications like scarring, pigmentation, contractures, and keloid formation, so the process of wound healing and the final outcome of this process are entirely dependent on how it is managed throughout the stages of wound healing.

The treatment principles are designed by analyzing the degree of burn and its systemic effect on the body. Initially, the case was managed with standard treatment protocol, i.e., intravenous fluid

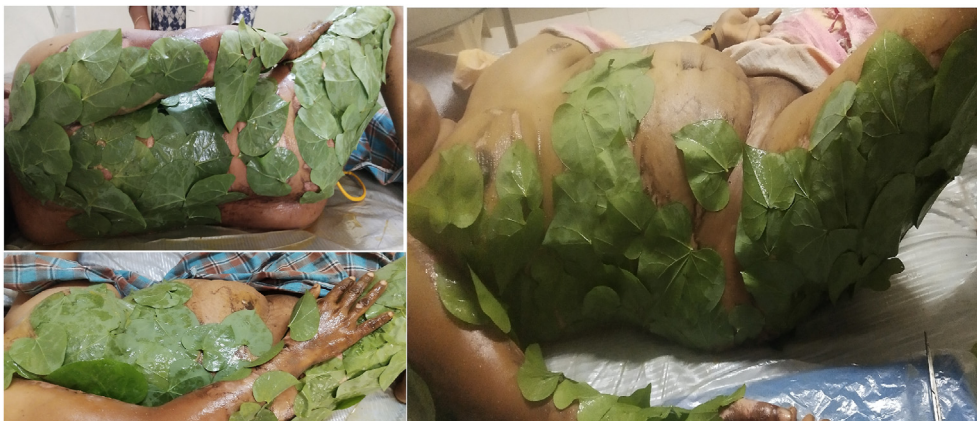

Fig. 3. Ropana ghrita application with Patraadaana(A)(B)(C).

Table 2
Therapeutic intervention and oral medicine

Sl No	Plan of care	Procedure	Duration(Days)							
			5-10	10-15	15-20	20-25	Follow up			
							25-35	35-45	45-60	
01	Modern medicine	IV Antibiotics like Injection Odicef-S (ceftriaxone with sulbactam) 1.5 grams Intravenous twice daily Intravenous metronidazole 100 millilitre thrice daily Injection Gentamycin 80 milligrams Intravenous twice daily	✓	✓						
02	Intravenous (IV) fluids	IV fluids like Dextrose Normal Saline (DNS), Ringer Lactate (RL) -1500 millilitre/day Tab Paracetamol 500 mg SOS	✓							
Ayurveda management (Internal)										
01	Tab.Triphala guggulu	250 milligrams two times daily after food	✓	✓	✓	✓	✓	✓	✓	✓
02	Tab.Punarnava mandoora	250 milligrams two times daily after food	✓	✓	✓	✓	✓	✓	✓	✓
03	Punarnavadi kashaya	10 millilitre thrice daily after foodwith warm water	✓	✓	✓	✓	✓	✓	✓	✓
04	Tab Chandrakala rasa	250 milligrams two times daily after food	✓	✓	✓	✓	✓	✓	✓	✓
05	Tab Kamadugha with mukta	250 milligrams two times daily after food	✓	✓	✓					
Wound Care (External)										
06	a) Wound healing	Ropaha ghrita application followed with <i>tinospora cordifolia</i> leaves bandage twice daily	✓	✓	✓	✓	✓	✓	✓	✓
	b) Fumigation	Twice daily	✓	✓	✓	✓	✓	✓	✓	✓

Table 3
Assessment of wound healing

		1st day	10th day	20th day	25th day	35th day	45th day	60th day
Pain (VAS)		10	7	4	2	1	—	—
Total body surface area (TBSA) RULE	Anterior trunk	08%	08%	6%	3%	2%	—	—
	Posterior trunk	12%	12%	6%	3%	2%	—	—
	Right upper limb	8%	8%	4%	3%	2%	—	—
	Right lower limb	10%	10%	5%	3%	2%	—	—
Floor	Anterior trunk	Yellow slough with centralized Eschar	Yellow slough with centralized Eschar	Yellow slough with centralized Eschar	Mild slough with#RGT	#RGT	*ES	*ES
	Posterior trunk	Yellow slough with centralized Eschar	Yellow slough with centralized Eschar	Yellow slough with centralized Eschar	Mild slough with #RGT	#RGT	*ES	*ES
	Right upper limb	Yellow slough with centralized Eschar	Yellow slough with centralized Eschar	Yellow slough with centralized Eschar	Mild slough with #RGT	#RGT	*ES	*ES
	Right lower limb	Yellow slough with centralized Eschar	Yellow slough with centralized Eschar	Yellow slough with centralized Eschar	Mild slough with #RGT	#RGT	*ES	*ES
Discharge	Anterior trunk	Purulent	Serous	Serous	—	—	—	—
	Posterior trunk	Purulent	Serous	Serous	—	—	—	—
	Right upper limb	Purulent	Serous	Serous	—	—	—	—
	Right lower limb	Purulent	Serous	Serous	—	—	—	—
Granulation tissue	Anterior trunk	—	No granulation tissue	No granulation tissue	#RGT	#RGT	—	—
	Posterior trunk	—	No granulation tissue	No granulation tissue	#RGT	#RGT	—	—
	Right upper limb	—	No granulation tissue	No granulation tissue	#RGT	#RGT	—	—
	Right lower limb	—	No granulation tissue	No granulation tissue	#RGT	#RGT	—	—
Epithelialisation	Anterior trunk	—	—	No epithelialisation	No epithelialisation	No epithelialisation	*ES	*ES
	Posterior trunk	—	—	No epithelialisation	No epithelialisation	No epithelialisation	*ES	*ES
	Right upper limb	—	—	No epithelialisation	No epithelialisation	No epithelialisation	*ES	*ES
	Right lower limb	—	—	No epithelialisation	No epithelialisation	No epithelialisation	*ES	*ES

VAS- Visual analogue scale, #RGT –Red granulation tissue, *ES – Epithelialisation.

resuscitation, broad-spectrum antibiotics, anti-inflammatory drugs, and analgesics.

The present case was treated as per the *Plushta* and *Durdagdha lines* of management, which highlights, external treatment modalities like application of *medicated ghee*, Covering the wound area with *Tinospora cordifolia* leaves, *wound fumigation*, and oral medications. The medicines used for topical application should possess properties like good tissue penetration, debridement property, antimicrobial, anti-inflammatory, and provide a moist environment for faster wound healing [12].

Ropana ghrita was used as an external application in the wound management because it contains ingredients like *Madhuchista* (beeswax), *Madhuka* (*Madhuca indica* Linn), *Lodhra* (*Symplocos racemosa* Linn), *Sarjarasa* (*Vateria indica* Linn), *Manjistha* (*Rubia cordifolia* Linn), *Chandana* (*Santalum album* Linn), *Murva* (*Morus alba* Linn), *Go-Ghrita* (Cow's ghee) [13]. The formulation possess properties like wound healing, increase complexion, *Twachya* (good for skin), *Raktaprasadana* (blood nourishment), *Sheeta* (cold potency), *Lekhana* (scraping), *Jantughna* (antimicrobial), etc which helps in the wound healing process. The *Go ghrita* possesses

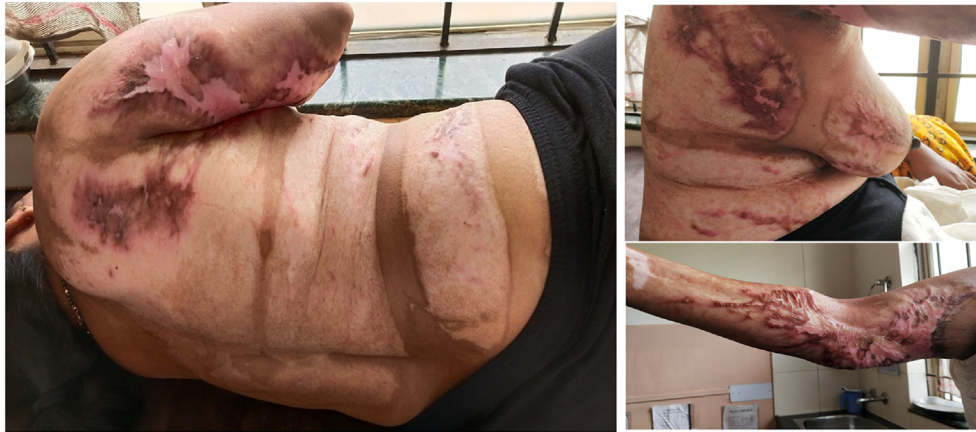

Fig. 4. 60 th day after treatment(A)(B)(C).

Rakshoghna (anti-microbial and anti-fungal), *Vranashodhana* (wound cleansing), *Vranaropana*, and *Vata pitta shamaka* (pacifies *Vata* and *pitta dosha*) properties with its *madhura vipaka*. This also helps in lubricating the wound surface and prevents eschar formation, as well as insensible loss of fluid from the burn site [14]. *Manjishtha* is another content, which has active phytochemicals like amino acids, saponin, carbohydrates, alkaloids, glycosides, phenolic compounds, and tannins. It functions as an antitoxic, blood detoxifying, antiseptic, and antioxidant agent [15].

Patraadaana has been the subject of numerous studies, including lotus leaves as an alternative dressing material [16], banana leaves in secondary burn wounds, etc [17]. These studies show that the non-adherent, waxy, and cool properties of the leaves provide a healthy platform for proper and faster-wound healing [16,17]. *Guduchi* (*T. cordifolia*, Linn) leaves are used in a wound indicated in *Pitta* and *Rakta dosha* predominant condition. The application of leaves for wound covering helps in the reduction of burning sensation and accelerates wound healing. In this study, the *Guduchi* leaves were applied over burn wounds after the application of *Ropanaghrita*. The waxy surface of the leaves has non-adherent properties, doesn't interfere with the intact epithelial tissue bed, and a provide moist wound environment thus facilitating wound healing [18].

The *Triphala guggulu* possesses the properties like scraping, anti-inflammatory and wound healing properties. Active phytochemicals in this formulation include glycosides, amino acids, flavonoids, tannin, steroids, protein, carbohydrates, and saponin [19]. *Triphala* inhibits both gram-positive and gram-negative bacteria growth [20]. Study on *Triphala* showed a decrease in the bacterial count in granulation tissue and an increase in collagen [21]. Increased epigallocate chingallate interaction with collagen contributes to increased tissue regeneration and hastens wound closure[22].

Kamadugha with *Mukta* was administered due to its properties like *Jantughna*, *raktaprasadana*, *kandugna*, *raktasthambaka* (coagulative), and *rasayana* (rejuvenative). *Kamadugharasa* is a *kharaliya* preparation (classical method of drug preparation) with *Kshara* nature (alkaline nature), which contains the ingredients like *Pra-va-la* (coral calx) and *Mukta* (pearl calcium). These ingredients possess *Deepana* (appetizer) and *Pachana* (digestive) properties which helps in *Vranaropana*. The preparation contains mostly the *Sheeta* (cold) *Virya* (potency) drugs, thus doing the *Pitta-shamana*, and helps in wound healing. *Kamadugha rasa* contains elements like sodium, iron, aluminum, potassium, and other essential minerals for a healthy body [23].

Punarnava Mandura contains mainly *Pippali*, which has *Agni Deepaka*, *Pachana*, *Vata anulomaka* (pacifies *Vata*), and *Rasayana* properties [24]. *Mandura Bhasma* (calx of iron rust) is *raktavidhikara* (improves hemoglobin). *Amalaki* (*Emblica officinalis*) is another ingredient that helps in the absorption of iron, thus helping in blood circulation. *Punarnavamandoora* is the best choice for oral iron therapy [25].

Chandrakala rasa contains *vangabhasma*, *lauhabhasma*, *rasa sindhoora*, and *abhrakabhasma* which acts on *Baahya-abhyantar-adaha* (internal and external burning sensation), *Brama* (giddiness), *Murcha* (unconsciousness), *Raktapitta* (bleeding disorder), etc [26].

Punarnavadi Kashaya possesses *Laghu guna* (lightness), *Katu rasa* (spicy), and *Ushna virya* (hot potency) which does *Amapachana* (improves indigestion), *Kledaghana* (reduces putrefaction) and reduces *shotha* (inflammation) [27]. The *Punarnava* (*Boerhavia diffusa* Linn) acts as an excellent anti-inflammatory and diuretic [28].

Wound fumigation is explained in the classics as *Rakshognavidhi* (anti-microbial/anti-fungal etc.) in *Janapadodhwamsa vyadhis* (communicable diseases), and *Vranachikitsa* (wound management) [29]. Direct reference in the classics regarding use of fumigation in burn injuries are not available, but cross-references to protect wounded from various entities are available. Various treatments are advised to protect the wounded person and the wound, among which fumigation is one. In this case, the *Dhoopana karma* was done with *Nimba* (*Azadirachta indica*), *Guggulu* (*Commiphora wightii*), *Ushira* (*Vitiveria zizanioides*), *Vacha* (*Acorus calamus*), *Sarsapa* (*Brassica campestris*), and *cow ghee* [29]. *Neem* has a very high sensitivity towards *Streptococcus pyogenes* and *Staphylococcus aureus*. The *Krimighna*, *Kandughna* and *kushtagna* properties of the drugs helped in wound healing and also prevented secondary infections [30].

Burn care demands extended hospitalization, which might be the major source of secondary infections [31]. This integrated approach accelerated wound healing and thereby shortened hospital stay; further research in this approach is necessary to provide evidence based results.

4. Conclusion

Burn management is a challenging task; even after complete recovery complications such as contractures, discoloration and keloid formation occur invariably. The present case was successfully treated with an integrated approach, i.e. *Ayurveda* and Modern medicine. The wound healed completely within 60 days of the treatment. The integrated approach minimized the hospital stay, contracture and enhanced the wound healing process with

minimal discoloration. Ayurvedic procedures such as fumigation, medicated ghee application, and *Tinospora* leaves bandaging has given promising results in the burn wound healing. It was a single case study; further research in this field is essential with inclusion of larger samples.

Informed consent

The informed consent regarding documentation and publication of the case was obtained from the patient.

Patient perspectives

The patient was satisfied and pleased with the care which was provided in the hospital. She is now able to perform her routine activities without discomfort.

Funding

Nil.

Authors contribution statement

Dr Pradeep S Shindhe, Dr Ramesh S Killedar carried out the clinical study and treated the patient. Data acquisition, documentation was done by Dr Priyanka K, Dr. Dhrushnu Prasannan, Dr Kirthi A. Manuscript was drafted by Dr Pradeep S Shindhe, Dr Ramesh Killedar, DrPriyanka. Manuscript editing and reviewing was done by Dr Pradeep S Shindhe, Dr Ramesh Killedar. All the authors are guarantors for the publication and data integrity.

Declaration of Competing Interest

Nil.

Acknowledgement

Dr Suhaskumar Shetty, Principal and Medical director, KAHER's Shri B. M K. Ayurveda Mahavidyalaya and Hospital, Belagavi.

References

- [1] Das S. A concise textbook of surgery Burns. 13,old mayor's court Kolkata: SD publications; 2020. p. 61.
- [2] Park J. Park's Text book of preventive and social medicine. 24th ed. India: M/S Banarasidas Bhanot; 2017. p. 428.
- [3] Gupta JL, Makhija LK, Bajaj SP. National programme for prevention of burn injuries. Indian J Plast Surg 2010 Sep;43(Suppl):S6–10. <https://doi.org/10.4103/0970-0358.70716>. PMID: 21321659; PMCID: PMC3038407.
- [4] Schaefer Timothy j, Szymanski Kiran D. Burn evaluation and management [Internet]. In: Stat pearls. Treasure Island (FL): Stat Pearls Publishing; 2021 Aug 11. 2022 Jan-. PMID: 28613492, <https://pubmed.ncbi.nlm.nih.gov/28613492/>.
- [5] Jeschke MG, van Baar ME, Choudhry MA, Chung KK, Gibran NS, Logsetty S. Burn injury. Nat Rev Dis Prim 2020 Feb 13;6(1):11. <https://doi.org/10.1038/s41572-020-0145-5>. PMID: 32054846; PMCID: PMC7224101.
- [6] Rajgopalshenoy K, Shenoy Anita. Manipal manual of surgery. New delhi: CBS publishers and distributors; 2020. p. 210–7.
- [7] Vaidya Jadavji Trikamji Acharya and Narayan Ram Acharya Kavyatirtha. Susrut samhita of susruta. Varanasi. Choukhambha Sanskrit Sansthan. 2012. sutrasthana12/16–26 P.52-53.
- [8] Vaidya Jadavji Trikamji Acharya and Narayan Ram Acharya Kavyatirtha. Susrut samhita of Susruta. Varanasi. Choukhambha Sanskrit Sansthan. 2012. Chikitsa sthana 1/8 p. 397.
- [9] Castera MR, Borhade MB. Fluid Management. [Updated 2021 Sep 8] [Internet]. In: StatPearls. Treasure Island (FL): StatPearls Publishing; 2022 Jan. Available from: <https://www.ncbi.nlm.nih.gov/books/NBK532305>.
- [10] Bates-Jensen BM, McCreath HE, Harputlu D, Patlan A. Reliability of the Bates-Jensen wound assessment tool for pressure injury assessment: the pressure ulcer detection study. Wound Repair Regen 2019 Jul;27(4):386–95. <https://doi.org/10.1111/wrr.12714>. Epub 2019 Mar 18. PMID: 30828890; PMCID: PMC6693585.
- [11] Laycock H, Valente J, Bantel, Nagy I. Peripheral mechanisms of burn injury-associated pain. Eur J Pharmacol 2013;716(1–3):169–78. <https://doi.org/10.1016/j.ejphar.2013.01.071>. Epub 2013 Mar 13. PMID: 23500208.
- [12] Dai T, Huang YY, Sharma SK, Hashmi JT, Kurup DB, Hamblin MR. Topical antimicrobials for burn wound infections. Recent Pat Anti-Infect Drug Discov 2010 Jun;5(2):124–51. <https://doi.org/10.2174/157489110791233522>. PMID: 20429870; PMCID: PMC2935806.
- [13] Vaidya Jadavji Trikamji Acharya and Narayan Ram Acharya Kavyatirtha. Susrut samhita of susruta. Varanasi. Choukhambha Sanskrit Sansthan. 2012. sutrasthana12/27, Pg.54.
- [14] Udawadia TE. Ghee and honey dressing for infected wounds. Indian J Surg 2011 Aug;73(4):278–83. <https://doi.org/10.1007/s12262-011-0240-7>. Epub 2011 Apr 6. PMID: 22851841; PMCID: PMC3144338.
- [15] Chandrashekar BS, Prabhakara S, Mohan T, Shabeer D, Bhandare B, Nalini M, et al. Characterization of *Rubia cordifolia* L. root extract and its evaluation of cardioprotective effect in Wistar rat model. Indian J Pharmacol 2018 Jan-Feb;50(1):12–21. doi: 10.4103/ijp.IJP_418_17. PMID: 29861523; PMCID: PMC5954628.
- [16] Okur ME, Karantas ID, Şenyiğit Z, Üstündağ Okur N, Sifaka PI. Recent trends on wound management: new therapeutic choices based on polymeric carriers. Asian J Pharm Sci 2020 Nov;15(6):661–84. <https://doi.org/10.1016/j.ajps.2019.11.008>. Epub 2020 Jan 23. PMID: 33363624; PMCID: PMC7750807.
- [17] Gore Madhuri A, Akolekar Deepika. Evaluation of banana leaf dressing for partial thickness burn wounds. Burns 2003;29(5):487–92. [https://doi.org/10.1016/s0305-4179\(03\)00050-0](https://doi.org/10.1016/s0305-4179(03)00050-0). PMID: 12880731.
- [18] Vaidya Jadavji Trikamji Acharya and Narayan Ram Acharya Kavyatirtha. Susrut samhita of susruta. Varanasi. Choukhambha Sanskrit Sansthan. 2012. chikitsasthana 1/112–118,pg 406.
- [19] Savariker SS, Barbhind MM, Halde UK, Kulkarni AP. Pharmaceutical and analytical evaluation of triphalagugulkalpa tablets. J Ayurveda Integr Med 2011 Jan;2(1):21–5. <https://doi.org/10.4103/0975-9476.78187>. PMID: 21731383; PMCID: PMC3121249.
- [20] Biradar YS, Jagatap S, Khandelwal KR, Singhanian SS. Exploring of antimicrobial activity of triphala mashi-an ayurvedic formulation. Evid Based Complement Alternat Med 2008;5(1):107–13. <https://doi.org/10.1093/ecam/nem002>. PMID: 18317557; PMCID: PMC2249739.
- [21] Kumar MS, Kirubanandan S, Sripriya R, Sehgal PK. Triphala promotes healing of infected full-thickness dermal wound. J Surg Res 2008 Jan;144(1):94–101. <https://doi.org/10.1016/j.jss.2007.02.049>. Epub 2007 Jul 27. PMID: 17662304.
- [22] Kumar MS, Kirubanandan S, Sripriya R, Sehgal PK. Triphala incorporated collagen sponge—a smart biomaterial for infected dermal wound healing. J Surg Res 2010 Jan;158(1):162–70. <https://doi.org/10.1016/j.jss.2008.07.006>. PMID: 19118845.
- [23] Meenakshi K, Vinteshwari N, Minaxi J, Vartika S. Effectiveness of Ayurveda treatment in urdhwaga amlapitta: a clinical evaluation. J Ayurveda Integr Med 2021 Jan-Mar;12(1):87–92. <https://doi.org/10.1016/j.jaim.2020.12.004>. Epub 2021 Feb 3. PMID: 33546994; PMCID: PMC8039346.
- [24] Pandya MG, Dave AR. A clinical study of Punarnava Mandura in the management of Pandu Roga in old age (geriatric anemia). Ayu 2014 Jul-Sep;35(3):252–60. <https://doi.org/10.4103/0974-8520.153735>. PMID: 26664234; PMCID: PMC4649575.
- [25] Rasheed A, Naik M, Mohammed-Haneefa KP, Arun-Kumar RP, Azeem AK. Formulation, characterization and comparative evaluation of Tri-vangabhasma: a herbo-mineral Indian traditional medicine. Pak J Pharm Sci 2014 Jul;27(4):793–800. PMID: 25015442.
- [26] Vaidya yadavji trikamjiacharya, sidhayogasangraha. New Delhi: Chaukamba publications; 2008. p. 96.
- [27] Sharma S. Chakradatta of chakrapani, shotha chikitsa. Ch. 43. vol. 10. New Delhi: Meherchand Lachmidas Publications; 2000. p. 254.
- [28] Mishra S, Aeri V, Gaur PK, Jachak SM. Phytochemical, therapeutic, and ethnopharmacological overview for a traditionally important herb: boerhavia diffusa Linn. BioMed Res Int 2014;2014:808302. <https://doi.org/10.1155/2014/808302>. Epub 2014 May 14. PMID: 24949473; PMCID: PMC4053255.
- [29] Vaidya Jadavji Trikamji Acharya, Narayan Ram Acharya Kavyatirtha. Commentary nibandhasangraha of sri dalhanacharya on susrutasamhita of susruta, Sutrasthana: [Chapter 5], verse19-32. Chikitsasthana: [Chapter 1],verse 80, Susruta samhita sutrasthana19/28, Varanasi:Chaukhamba Surbharati Prakashan, 2012, 21.
- [30] Balkrishna A, Yagyadev S, Vipradev S, Singh K, Varshney Y, Rastogi S, et al. Vishaghn dhoop, nano-scale particles with detoxifying medicinal fume, exhibits robust anti-microbial activities: implications of disinfection potentials of a traditional ayurvedic air sterilization technique. 27: 2515690X211068832 J Evid Based Integr Med 2022 Jan-Dec. <https://doi.org/10.1177/2515690X211068832>. PMID: 34985370; PMCID: PMC8744077.
- [31] Onah CN, Allmendinger R, Handl J, Dunn KW. Surviving burn injury: drivers of length of hospital stay. Int J Environ Res Publ Health 2021 Jan 18;18(2):761. <https://doi.org/10.3390/ijerph18020761>. PMID: 33477442; PMCID: PMC7829802.